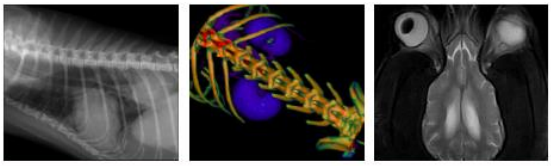

SonoPath.com
1-800-838-4268 info@sonopath.com

PATIENT

Lola Colon

SPECIES

Feline

BREED

DSH

SEX

Spayed Female

AGE

13 Years

INTERPRETED BY

Sebastian Schaub, DVM
Dr. med. vet. DipECVDI

HOSPITAL NAME

Mobile Pet Imaging

REFERRING VET

Meaux

INVOICE

51549

DATE

4-15-22

PRESENTING CLINICAL SIGNS

Sarcoma left axilla. Had chemo 3-4 weeks ago.

COMPUTED TOMOGRAPHY OF THE THORAX AND ABDOMEN

A high resolution pre- and post-contrast CT study of the abdomen and a post-contrast CT study of the thorax are provided for review.

COMPUTED TOMOGRAPHIC FINDINGS

Thorax

In the subcutaneous tissue at the caudal aspect of the left axillary region, a multiloculated, heterogeneous contrast enhancing ill-defined mass, measuring 5.1 x 1.9 x 2.8 cm in size, is visible. Multiple small subcutaneous nodules are appreciated along the proximal aspect of the left front limb/thoracic wall.

The sternal, cranial mediastinal and tracheobronchial lymph nodes are small elongated with a normal short-to-long-axis-ratio is < 0.5, the attenuation and contrast enhancement pattern is uniform and considered within normal limits.

The cardiovascular structures including the pulmonary vasculature are within normal limits.

Throughout the lung parenchyma, randomly distributed, well-defined variable sized, soft tissue attenuating nodular lesions are visible, measuring up to 10 mm in size.

Small incidental gas pockets are seen within the esophageal lumen, there is no evidence of abnormal dilation.

Abdomen

The serosal fat presents normal attenuation behavior. There is no evidence of peritoneal effusion or peritonitis.

Both kidneys present within normal limits for size, shape and organ architecture. In the lateral aspect of the caudal pole of the left kidney, a well-defined, roundish parenchymal filling defect is appreciated.

The adrenal glands are within normal limits for size, shape and organ architecture.

Both liver and spleen present with normal shape, even surface, uniformly attenuating parenchyma and homogeneous contrast enhancement, unremarkable.

The pancreas is evenly contoured, the pancreatic parenchyma is homogeneous and presents uniform contrast enhancement.

The position, delineation, wall and content of the gastrointestinal tract are considered within normal limits throughout.

The vertebral endplates L7/S1 present mild spondylosis formation.

PATIENT

Lola Colon

SPECIES

Feline

BREED

DSH

SEX

Spayed Female

AGE

13 Years

INTERPRETED BY

Sebastian Schaub, DVM
Dr. med. vet. DipECVDI

HOSPITAL NAME

Mobile Pet Imaging

REFERRING VET

Meaux

INVOICE

51549

DATE

4-15-22

COMPUTED TOMOGRAPHIC DIAGNOSIS

- History of sarcoma left axillary region with multiple variable sized nodular subcutaneous lesions
- Structured nodular interstitial lung pattern
- Solitary pulmonary cyst left kidney
- Spondylosis deformans

INTERPRETATION OF THE FINDINGS & FURTHER RECOMMENDATIONS

The findings are fitting the history of sarcoma in the left axillary region with multiple subcutaneous nodules and a larger mass level with the proximal left brachium & thoracic wall.

The lung pattern is consistent with pulmonary metastatic spread.

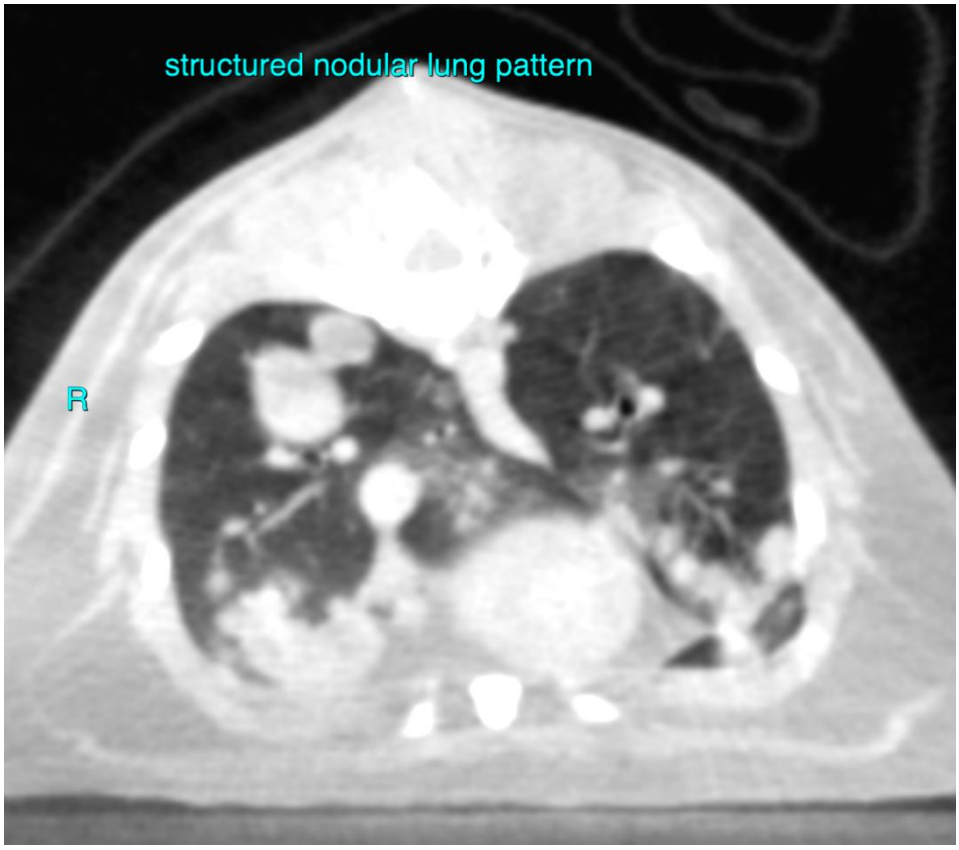

SonoPath Teleradiology

MOBILE PET IMAGING®
VETERINARY CT SCANS & FLUOROSCOPIES

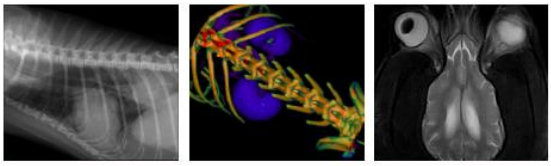

EDUCATIONAL TELECONSULTATION SERVICES™

SonoPath.com
1-800-838-4268 info@sonopath.com

PATIENT

Lola Colon

SPECIES

Feline

BREED

DSH

SEX

Spayed Female

AGE

13 Years

INTERPRETED BY

Sebastian Schaub, DVM
Dr. med. vet. DipECVDI

HOSPITAL NAME

Mobile Pet Imaging

REFERRING VET

Meaux

INVOICE

51549

DATE

4-15-22

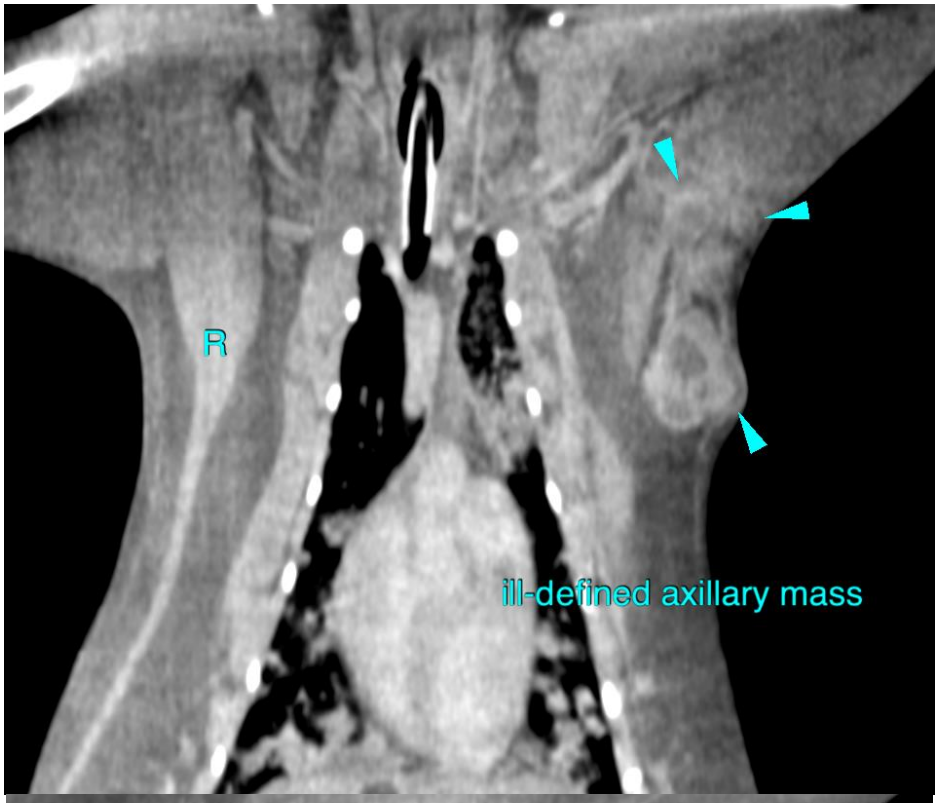

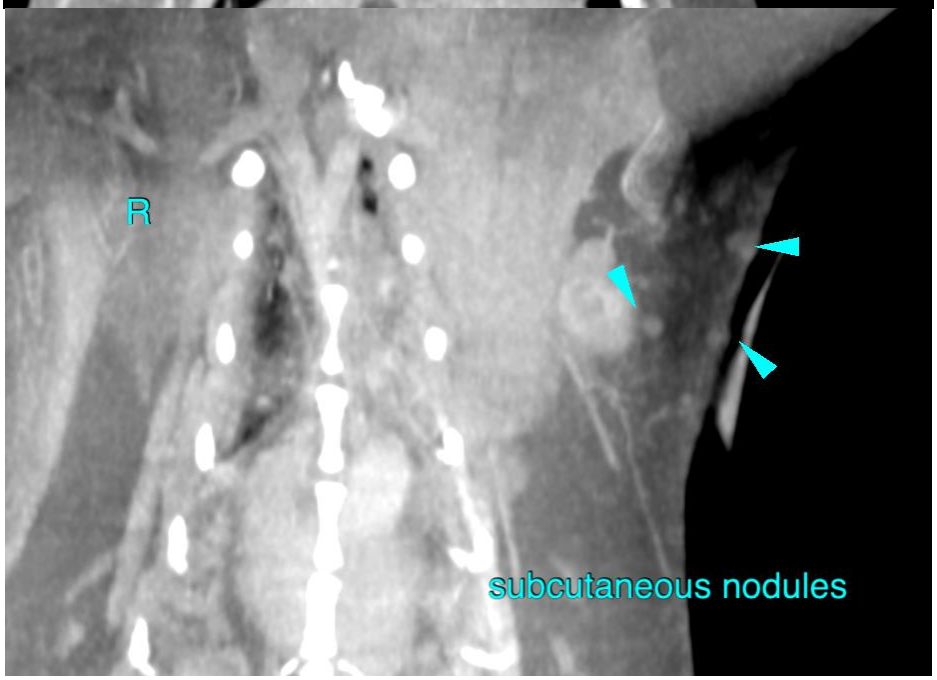

SonoPath Teleradiology

MOBILE PET IMAGING®
VETERINARY CT SCANS & FLUOROSCOPIES

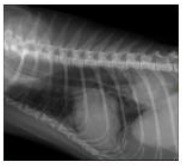
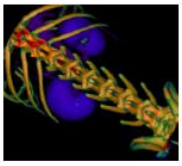
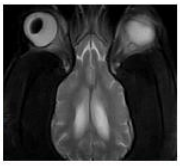

EDUCATIONAL TELECONSULTATION SERVICES™

SonoPath.com
1-800-838-4268 info@sonopath.com

PATIENT

Lola Colon

SPECIES

Feline

BREED

DSH

SEX

Spayed Female

AGE

13 Years

INTERPRETED BY

Sebastian Schaub, DVM
Dr. med. vet. DipECVDI

HOSPITAL NAME

Mobile Pet Imaging

REFERRING VET

Meaux

INVOICE

51549

DATE

4-15-22

The information and recommendations provided are based on the images presented by the referring veterinarian/sonographer. No evaluation can be communicated regarding pathology that was not visible in the image/video clips provided.

Thank you for this referral. If the clinical or image interpretation does not parallel your findings or if I can be of any further assistance please contact me.

Sebastian Schaub, Sebastian Schaub, DVM, Dr. med. vet. DipECVDI
sebast.schaub@gmail.com