

**PATIENT PRESENTING CLINICAL SIGNS**

Comet Amador History: Head tilt after ear cleaning due to Hx of ear mites. Suspected tympanic membrane ruptured.  
Abnormal PE/Chem/CBC/UA Results:

**SPECIES**

Lagamorph

**COMPUTED TOMOGRAPHIC STUDY OF THE SKULL**

A high resolution pre- and post-contrast CT study of the skull is provided for review.

**BREED**

Rabbit

**COMPUTED TOMOGRAPHIC FINDINGS**

The pictured parts of the dentition are complete and unremarkable in all jaw quadrants.

**SEX**

Intact Male

The nasal cavity presents the expected aerated spaces between thin & even conchae and turbinates with smooth mucosal lining.

**AGE**

8 Months

Both tympanic bullae are aerated, the mucosal lining is not seen, the bony wall is smooth and thin. A mild soft tissue swelling is seen in the region of the dorsal aspect of the left tympanic membrane. The left external ear canal contains a small amount of non-contrast enhancing soft tissue material.

**INTERPRETED BY**

Sebastian Schaub, DVM  
Dr. med. vet. DipECVDI

The brain presents no deviation from normal anatomy and symmetry. The brain parenchyma is homogeneous and within normal limits for attenuation and distribution of contrast enhancement. The ventricular system is non-dilated and symmetric.

**COMPUTED TOMOGRAPHIC DIAGNOSIS****HOSPITAL NAME**

Mobile Pet Imaging  
CFL

- History of parasitic otitis externa
- Mild soft tissue swelling region of left tympanic membrane
- No evidence of otitis media

**INTERPRETATION OF THE FINDINGS & FURTHER RECOMMENDATIONS****REFERRING VET**

Dr. Meaux

The mild swelling in the region of the left tympanic membrane can indicate a small amount of exudate or small hematoma. Evaluation of the integrity of the tympanic membrane will warrant visual evaluation.

**INVOICE**

14755

Rule out Encephalitozoon infection as source for the head tilt as well.

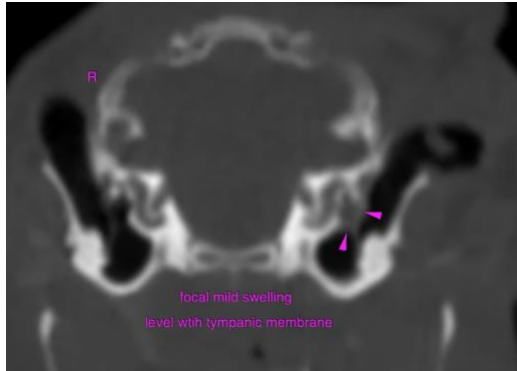
**DATE**

4/15/22



**PATIENT**

Comet Amador



**SPECIES**

Lagomorph

**BREED**

Rabbit

**The information and recommendations provided are based on the images presented by the referring veterinarian/sonographer. No evaluation can be communicated regarding pathology that was not visible in the image/video clips provided.**

**SEX**

Intact Male

Thank you for this referral. If the clinical or image interpretation does not parallel your findings or if I can be of any further assistance please contact me.

**AGE**

8 Months

**Sebastian Schaub**, Sebastian Schaub, DVM, Dr. med. vet. DipECVDI  
sebast.schaub@gmail.com

**INTERPRETED BY**

Sebastian Schaub, DVM  
Dr. med. vet. DipECVDI

**HOSPITAL NAME**

Mobile Pet Imaging  
CFL

**REFERRING VET**

Dr. Meaux

**INVOICE**

14755

**DATE**

4/15/22