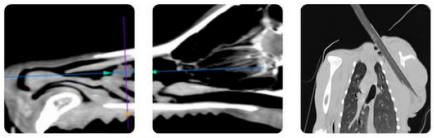

Teleradiology
Educational Teleconsultation Services™

PATIENT
Merle Franklin

SPECIES
Canine

BREED
French Bulldog

SEX
MN

AGE
5Y

WEIGHT
14.5

INTERPRETED BY
Sebastian Schaub, DVM
Dr. med. vet.
DipECVDI

IMAGING PERFORMED BY
ARR/ND

HOSPITAL NAME
Southern Oregon Veterinary Specialty Center

REFERRING VET
Kimberly Winters

INVOICE
74590

DATE
4-14-26

PRESENTING CLINICAL SIGNS

4/13: acute onset epistaxis, blood clots, blood in laryngeal region on sedated exam
Abnormal PE/Chem/CBC/UA Results: Indirect blood pressure: 100 mmHg PT/PTT: 14/81 (WNL)
CBC: Unremarkable; HCT 46.1%. Chem17/lytes: ALT 185 U/L; amylase 1760 U/L; lipase 2888
Thoracic radiographs (3-view): Mild ventral spondylosis deformans and hemivertebrae of the thorax; no gross metastatic disease, aspiration pneumonia, or primary pulmonary tumors identified. 4Dx: neg x4

COMPUTED TOMOGRAPHY OF THE SKULL

A high resolution pre- and post-contrast CT study of the skull is provided for review.

COMPUTED TOMOGRAPHIC FINDINGS

The skull has a brachycephalic conformation with significant crowding and rotation of the maxillary premolar teeth.

Multiple teeth are absent. Triadan 109, 110, 209, 210, 310 and 410 present a moderate widened periodontal space.

The nasal cavity presents the expected aerated spaces – but a small amount of fluid attenuating material that is attached to multiple conchae – between thin & even conchae and turbinates with smooth mucosal lining.

Both temporomandibular joints present congruent joint spaces with even subchondral bone surfaces and are considered within normal limits.

Both tympanic bullae are aerated, the mucosal lining is not seen, the bony wall is smooth and thin. The external ear canals are within normal limits.

The brain presents no deviation from normal anatomy and symmetry. The brain parenchyma is homogeneous and within normal limits for attenuation and distribution of contrast enhancement. The ventricular system is non-dilated and symmetric.

The submandibular and medial retropharyngeal lymph nodes are small and elongated with a normal short-to-long-axis-ratio is < 0.5, the attenuation and contrast enhancement pattern is uniform.

The arch of C1 is incompletely fused in the midline.

COMPUTED TOMOGRAPHIC DIAGNOSIS

- Very small amount of fluid attenuating material in nasal cavity – likely retained blood
- Multiple absent teeth
- Periodontal disease multiple molar teeth
- Incidental incomplete ossification ventral arch C1

INTERPRETATION OF THE FINDINGS & FURTHER RECOMMENDATIONS

The CT study reveals no abnormalities that do explain the epistaxis. Possible causes for epistaxis include immune mediated disease, non-specific rhinitis (e.g. lymphocytic plasmocytic), hyperviscosity syndrome (e.g. Leishmaniosis), other causes for coagulopathy or systemic hypertension.

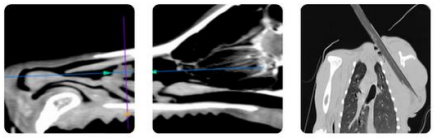

Teleradiology
Educational Teleconsultation Services™

PATIENT
Merle Franklin

SPECIES
Canine

BREED
French Bulldog

SEX
MN

AGE
5Y

WEIGHT
14.5

INTERPRETED BY
Sebastian Schaub, DVM Dr. med. vet. DipECVDI

IMAGING PERFORMED BY
ARR/ND

HOSPITAL NAME
Southern Oregon Veterinary Specialty Center

REFERRING VET
Kimberly Winters

INVOICE
74590

DATE
4-14-26

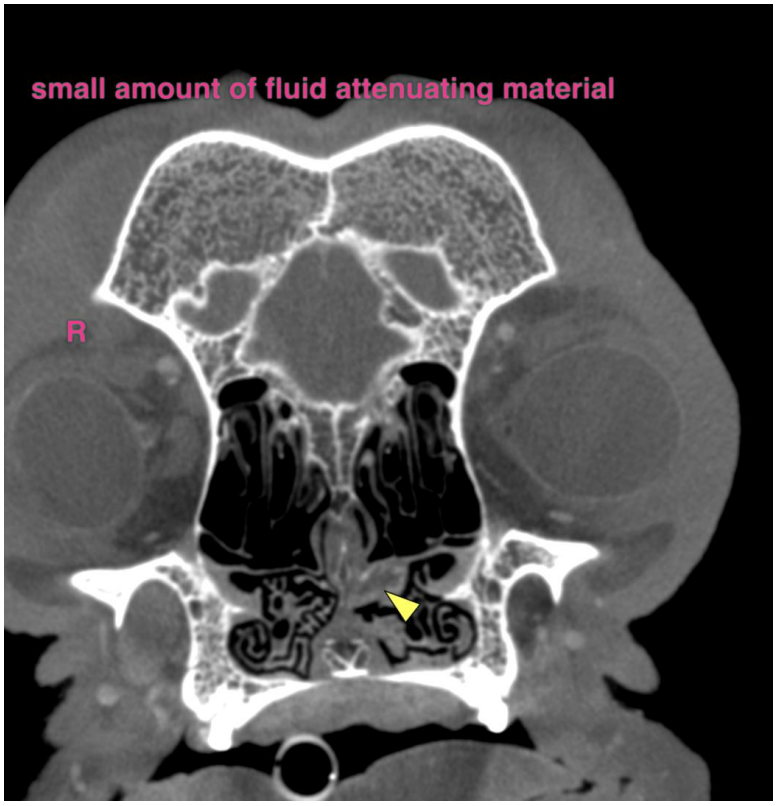

The information and recommendations provided are based on the images presented by the referring veterinarian/sonographer. No evaluation can be communicated regarding pathology that was not visible in the image/video clips provided.

Thank you for this referral. If the clinical or image interpretation does not parallel your findings or if I can be of any further assistance please contact me.

Sebastian Schaub, Sebastian Schaub, DVM, Dr. med. vet. DipECVDI
info@sonopath.com