



PATIENT

Luna Thompson

SPECIES

Canine

BREED

Shepherd Mix

SEX

Spayed Female

AGE

5Y

WEIGHT

47lbs

INTERPRETED BY

Sebastian Schaub, DVM
Dr. med. vet.
DipECVDI

IMAGING PERFORMED BY

Sidney

HOSPITAL NAME

East Hill Animal
Hospital

REFERRING VET

Laura Hall

INVOICE

74589

DATE

4-14-26

PRESENTING CLINICAL SIGNS

mass on bridge of nose for 1.5y.
not growing.

Sneezing.

OS enucleation scheduled.

Abnormal PE/Chem/CBC/UA Results: FNA- blood bw- wnl

COMPUTED TOMOGRAPHY OF THE SKULL

A high resolution pre- and post-contrast CT study of the skull is provided for review.

COMPUTED TOMOGRAPHIC FINDINGS

The pictured parts of the dentition are complete and unremarkable in all jaw quadrants.

The nasal cavity presents the expected aerated spaces between thin & even conchae and turbinates with smooth mucosal lining. In the subcutaneous tissue at the rostradorsal aspect of the nasal bones, an ill-defined, uniform soft tissue attenuating and heterogeneous contrast enhancing swelling is appreciated; measuring approximately 16 x 7 x 22 mm.

Both temporomandibular joints present congruent joint spaces with even subchondral bone surfaces and are considered within normal limits.

COMPUTED TOMOGRAPHIC DIAGNOSIS

- Subcutaneous soft tissue mass bridge of nose without osseous involvement

INTERPRETATION OF THE FINDINGS & FURTHER RECOMMENDATIONS

The subcutaneous mass on the bridge of the nose is not specific, due to the chronicity the odds for an inflammatory origin such as granuloma formation are high. Anyway underlying soft tissue neoplasia such like mast cell tumor is a potential as well. Repeating FNA sampling or biopsy can be performed for specification.



PATIENT

Luna Thompson

SPECIES

Canine

BREED

Shepherd Mix

SEX

Spayed Female

AGE

5Y

WEIGHT

47lbs

INTERPRETED BY

Sebastian Schaub, DVM
Dr. med. vet.
DipECVDI

IMAGING PERFORMED BY

Sidney

HOSPITAL NAME

East Hill Animal
Hospital

REFERRING VET

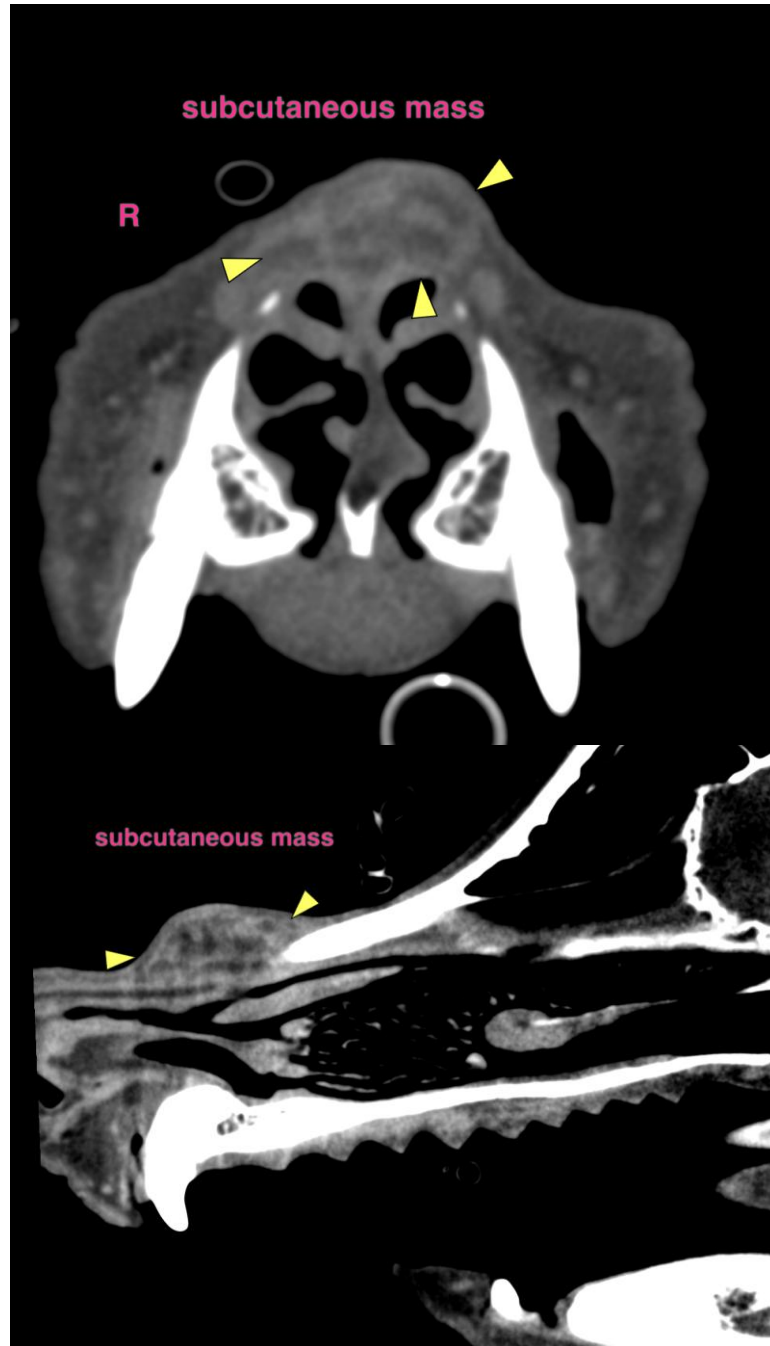
Laura Hall

INVOICE

74589

DATE

4-14-26





PATIENT

Luna Thompson

SPECIES

Canine

BREED

Shepherd Mix

SEX

Spayed Female

AGE

5Y

WEIGHT

47lbs

INTERPRETED BY

Sebastian Schaub, DVM
Dr. med. vet.
DipECVDI

IMAGING PERFORMED BY

Sidney

HOSPITAL NAME

East Hill Animal
Hospital

REFERRING VET

Laura Hall

INVOICE

74589

DATE

4-14-26

The information and recommendations provided are based on the images presented by the referring veterinarian/sonographer. No evaluation can be communicated regarding pathology that was not visible in the image/video clips provided.

Thank you for this referral. If the clinical or image interpretation does not parallel your findings or if I can be of any further assistance please contact me.

Sebastian Schaub, Sebastian Schaub, DVM, Dr. med. vet. DipECVDI
info@sonopath.com