



**PATIENT PRESENTING CLINICAL SIGNS**

Skunky Ward History: HBC 5 yrs ago. Over the past year has developed feline hyperesthesia syndrome suspected due to chronic neuropathic pain. Goal to r/o spinal cord compression, possible hip issue. Wire left femur from previous fracture repair.

**SPECIES COMPUTED TOMOGRAPHIC STUDY OF THE ENTIRE SPINE**

Feline A plain CT study of the cervical, thoracic and lumbar spine is provided for review.

**BREED COMPUTED TOMOGRAPHIC FINDINGS**

DSH The osseous and soft tissue structures along the cervical, thoracic and lumbar spine present no abnormalities.

**SEX** The osseous and surrounding soft tissue structures of the pelvis are within normal limits. Both coxofemoral joints present smooth osseous margins and congruent joint spaces.

Neutered Male

Multiple small (<1 mm) mineral attenuating calculi are seen on the dorsal urinary bladder wall.

**AGE COMPUTED TOMOGRAPHIC DIAGNOSIS**

7 Years

- Small amount of bladder sand, without signs of mechanical obstruction
- Normal cervical, thoracic and lumbar spine
- Normal pelvis and coxofemoral joints

**INTERPRETED BY**

Sebastian Schaub,  
DVM Dr. med. vet.  
DipECVDI

**INTERPRETATION OF THE FINDINGS & FURTHER RECOMMENDATIONS**

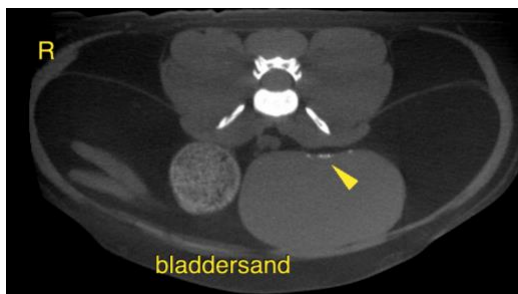
The CT study presents without abnormalities, explaining the described clinical signs. In case of strong suspicion for underlying compressive myelopathy or intradural lesion, recommend complementing workup by a post-contrast CT study ± myelographic CT study or MRI study of the spine.

**HOSPITAL NAME**

Bridgwater VH & WC

**REFERRING VET**

Dr. C. Ward



**INVOICE**

22014

**The information and recommendations provided are based on the images presented by the referring veterinarian/sonographer. No evaluation can be communicated regarding pathology that was not visible in the image/video clips provided.**

**DATE**

4/14/23



**PATIENT**

Thank you for this referral. If the clinical or image interpretation does not parallel your findings or if I can be of any further assistance please contact me.

Skunky Ward

**SPECIES**

**Sebastian Schaub**, Sebastian Schaub, DVM, Dr. med. vet. DipECVDI  
[sebast.schaub@gmail.com](mailto:sebast.schaub@gmail.com)

Feline

**BREED**

DSH

**SEX**

Neutered Male

**AGE**

7 Years

**INTERPRETED BY**

Sebastian Schaub,  
DVM Dr. med. vet.  
DipECVDI

**HOSPITAL NAME**

Bridgwater VH & WC

**REFERRING VET**

Dr. C. Ward

**INVOICE**

22014

**DATE**

4/14/23