



PATIENT

Fredrico Second
Chance for Homeless
Pets

PRESENTING CLINICAL SIGNS

Sneezing blood only from left nasal passage, intermittent vomiting, hypoalbuminemia

SPECIES

Feline

COMPUTED TOMOGRAPHY OF THE SKULL

A high resolution pre- and post-contrast CT study of the skull is provided for review.

BREED

DSH

COMPUTED TOMOGRAPHIC FINDINGS

Triadan 206 and 301 are absent. Triadan 304 presents with resorptive lesions.

SEX

MN

A small amount of fluid attenuating material is seen in the most rostral aspect of the nasal cavity bilaterally. The remainder of the nasal cavity present the expected aerated spaces between thin & even conchae and turbinates with smooth mucosal lining.

Both temporomandibular joints present congruent joint spaces with even subchondral bone surfaces and are considered within normal limits.

AGE

7 Years

Both tympanic bullae are aerated, the mucosal lining is not seen, the bony wall is smooth and thin. The external ear canals are within normal limits.

The brain presents no deviation from normal anatomy and symmetry. The brain parenchyma is homogeneous and within normal limits for attenuation and distribution of contrast enhancement. The ventricular system is non-dilated and symmetric.

INTERPRETED BY

Sebastian Schaub, DVM
Dr. med. vet. DipECVDI

The submandibular and medial retropharyngeal lymph nodes are small and elongated with a normal short-to-long-axis-ratio is < 0.5, the attenuation and contrast enhancement pattern is uniform.

HOSPITAL NAME

Mountain West
Veterinary Hospital

COMPUTED TOMOGRAPHIC DIAGNOSIS

- Equivocal rhinitis
- Absent triadan 206 and 301
- Resorptive lesions 304

REFERRING VET

Melanie Thompson

INTERPRETATION OF THE FINDINGS & FURTHER RECOMMENDATIONS

The mild amount of exudate in the nasal cavity is suggestive for rhinitis – primary viral is most common. There is no evidence of nasal mass or nasal passage obstruction. A nasal swap for PCR/microbial culture or rhinoscopy including sampling for histopathology might be considered as advanced diagnostic test.

INVOICE

51535

DATE

4-14-22



PATIENT

Fredrico Second
Chance for Homeless
Pets

SPECIES

Feline

BREED

DSH

SEX

MN

AGE

7 Years

INTERPRETED BY

Sebastian Schaub, DVM
Dr. med. vet. DipECVDI

HOSPITAL NAME

Mountain West
Veterinary Hospital

REFERRING VET

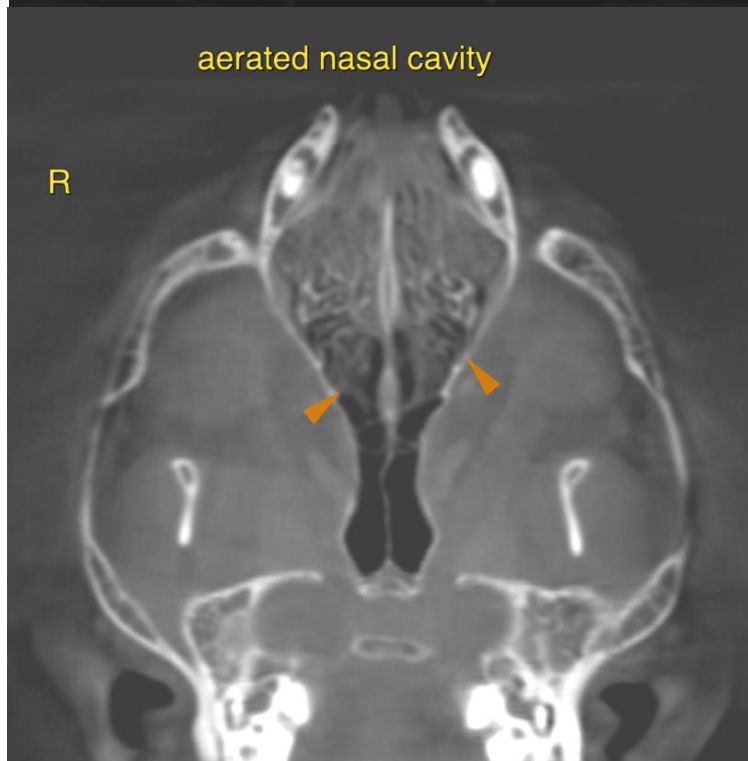
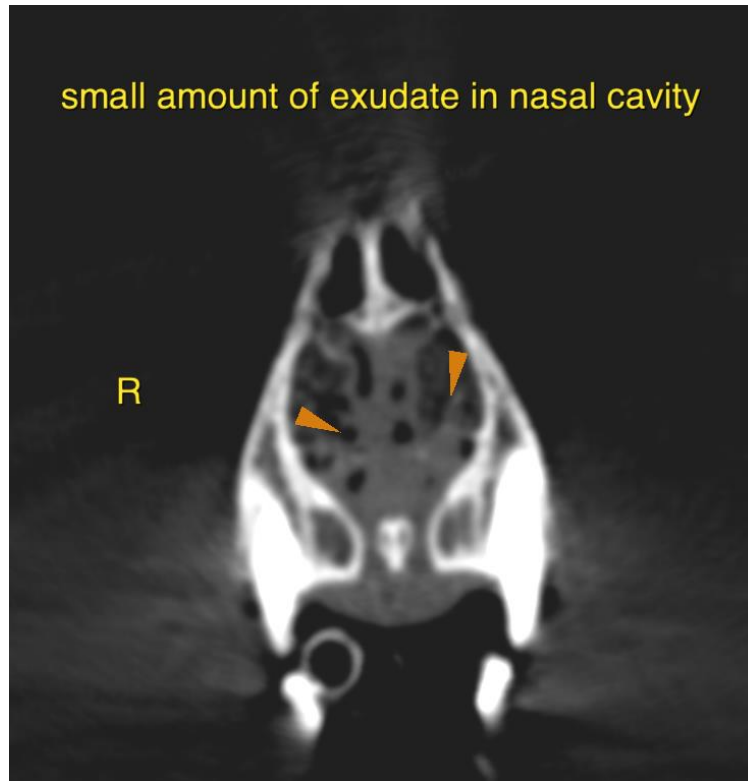
Melanie Thompson

INVOICE

51535

DATE

4-14-22





PATIENT

Fredrico Second
Chance for Homeless
Pets

SPECIES

Feline

BREED

DSH

SEX

MN

AGE

7 Years

INTERPRETED BY

Sebastian Schaub, DVM
Dr. med. vet. DipECVDI

HOSPITAL NAME

Mountain West
Veterinary Hospital

REFERRING VET

Melanie Thompson

INVOICE

51535

DATE

4-14-22

The information and recommendations provided are based on the images presented by the referring veterinarian/sonographer. No evaluation can be communicated regarding pathology that was not visible in the image/video clips provided.

Thank you for this referral. If the clinical or image interpretation does not parallel your findings or if I can be of any further assistance please contact me.

Sebastian Schaub, Sebastian Schaub, DVM, Dr. med. vet. DipECVDI
sebast.schaub@gmail.com