



**PATIENT**

Cheeko Kuehn

**PRESENTING CLINICAL SIGNS**

swelling on side right side of body, , started with limping week ago (back right) for about a week long - think maybe he was jumping off stairs and landed wrong ,but getting better

**SPECIES**

Canine

**RADIOGRAPHIC STUDY OF THE ABDOMEN**

Radiographs of the abdomen in three imaging planes are provided for review.

**BREED**

Chihuahua

The body condition score is 9/9.

The surrounding bony structures are within normal limits.

**SEX**

Male

No abnormalities of the extraabdominal soft tissues are noted. The abdominal wall is smooth and thin.

The serosal detail is maintained throughout the peritoneal and retroperitoneal space.

**AGE**

9

The hepatic volume is moderately increased the liver is protruding beyond the costal arch; the gastric axis is deviated caudally. The caudoventral hepatic margins are rounded.

The splenic head is in the anticipated position and within normal limits for size and opacity. The splenic body and tail are considered normal for position, size, shape and opacity.

**INTERPRETED BY**

Sebastian Schaub, DVM  
Dr. med. vet. DipECVDI

Both kidneys are seen and present with normal size, shape, delineation and opacity. The urinary bladder is in its anticipated position. No radiopaque calculi are noted throughout the upper and lower urinary tract.

The stomach is in its anticipated position and is empty.

**HOSPITAL NAME**

St. Catherine's Animal  
Hospital

The small intestinal loops are of even diameter and non-dilated, a small amount of gas is seen within the small intestinal loops and considered within normal limits.

The colon is seen in the expected position and presents with appropriate content.

**REFERRING VET**

Dr. Mena

**RADIOGRAPHIC DIAGNOSIS**

- Obesity
- Hepatomegaly

**INVOICE**

51545

**INTERPRETATION OF THE FINDINGS & FURTHER RECOMMENDATIONS**

No specific swelling is appreciated, but significant amounts of subcutaneous & intraabdominal fat.

**DATE**

4-14-22

Potentials for the hepatomegaly include metabolic hepatic disease/steroid induced hepatopathy, hepatitis or neoplastic infiltration. Ultrasound including FNA sampling can be used as minimally advanced diagnostic tests.

No additional clinically relevant abnormalities are appreciated.



**PATIENT**

Cheeko Kuehn

**SPECIES**

Canine

**BREED**

Chihuahua

**SEX**

Male

**AGE**

9

**INTERPRETED BY**

Sebastian Schaub, DVM  
Dr. med. vet. DipECVDI

**HOSPITAL NAME**

St. Catherine's Animal  
Hospital

**REFERRING VET**

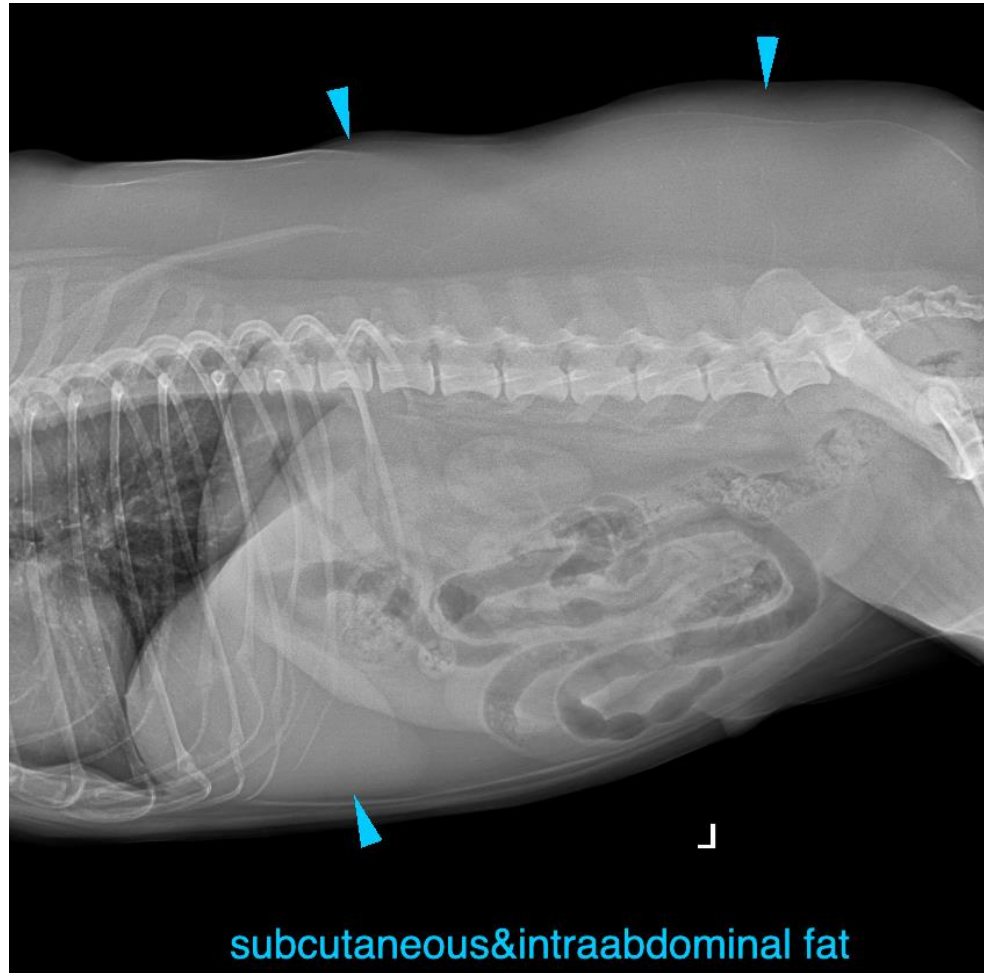
Dr. Mena

**INVOICE**

51545

**DATE**

4-14-22



The information and recommendations provided are based on the images presented by the referring veterinarian/sonographer. No evaluation can be communicated regarding pathology that was not visible in the image/video clips provided.

Thank you for this referral. If the clinical or image interpretation does not parallel your findings or if I can be of any further assistance please contact me.

**Sebastian Schaub**, Sebastian Schaub, DVM, Dr. med. vet. DipECVDI  
sebast.schaub@gmail.com