



PATIENT

Macy Scalf

SPECIES

Canine

BREED

Shar Pei Mix

SEX

Female Spayed

AGE

4Y, 4M

WEIGHT

67lbs

INTERPRETED BY

Sebastian Schaub, DVM
Dr. med. vet.
DipECVDI

IMAGING PERFORMED BY

Dr. Burge

HOSPITAL NAME

Wilson Veterinary
Hospital

REFERRING VET

Dr. Vitale

INVOICE

74569

DATE

4-13-26

PRESENTING CLINICAL SIGNS

Pet presented for left hindlimb lameness on 3/17.

Positive direct and indirect drawer was present, supporting CrCL rupture, but there was also significant SQ swelling present cranial and distal to the stifle.

Cytology and culture of the SQ fluid was consistent with seroma fluid. Pet has a history of RIGHT hindlimb TPLO in 2025 and was recently seen for recurrent lameness in February 2026 that resolved with simplicef and galliprant.

CT to evaluate potential source of swelling/seroma that is not attributable to CrCL tear.

Pet was treated with a tapering dose of prednisone that has significantly decreased the swelling in the left hind leg; last dose of prednisone was yesterday

COMPUTED TOMOGRAPHY OF THE PELVIS AND HIND LIMBS

A high resolution plain CT study of the pelvis and hind limbs is provided for review.

COMPUTED TOMOGRAPHIC FINDINGS

The lumbosacral intervertebral disc is protruding into the vertebral canal, occupying approximately $\leq 25\%$ of the cross-sectional area of the vertebral canal at the same level.

The osseous and surrounding soft tissue structures of the pelvis are within normal limits. Both coxofemoral joints present smooth osseous margins and congruent joint spaces.

The volume of the musculature of the left hind limb is moderately decreased.

The periarticular bones of both stifle joints present mild (right) to moderate (left) osteophyte new bone formation. Both stifle joints present a moderate intracapsular soft tissue swelling. At the medioproximal aspect of the right tibia, a TPLO implant is appreciated. The osteotomy of the right proximal tibia is completely filled with trabecular osseous material.

The osseous and surrounding soft tissue structures of both tarsal joints are unremarkable.

COMPUTED TOMOGRAPHIC DIAGNOSIS

- History of surgical management of pathology of the cranial cruciate ligament of the right stifle joint via TPLO
- Moderate osteoarthritis both stifle joints, L>R
- Articular swelling stifle joint bilaterally
- Disuse atrophy musculature left hind limb
- Intervertebral disc herniation lumbosacral junction without compressive myelopathy
- Normal pelvis & coxofemoral joints
- Normal tarsal joints

INTERPRETATION OF THE FINDINGS & FURTHER RECOMMENDATIONS

The degenerative joint disease of the left stifle joint is supporting the diagnosis of pathology of the cranial cruciate ligament \pm meniscal disease of the left stifle joint as a likely cause for the left hind limb lameness - the diagnosis is confirmed by the clinically appreciated positive drawer sign & tibial compression test.

No additional clinically relevant abnormalities are appreciated.



PATIENT

Macy Scalf

SPECIES

Canine

BREED

Shar Pei Mix

SEX

Female Spayed

AGE

4Y, 4M

WEIGHT

67lbs

INTERPRETED BY

Sebastian Schaub, DVM
Dr. med. vet.
DipECVDI

IMAGING PERFORMED BY

Dr. Burge

HOSPITAL NAME

Wilson Veterinary
Hospital

REFERRING VET

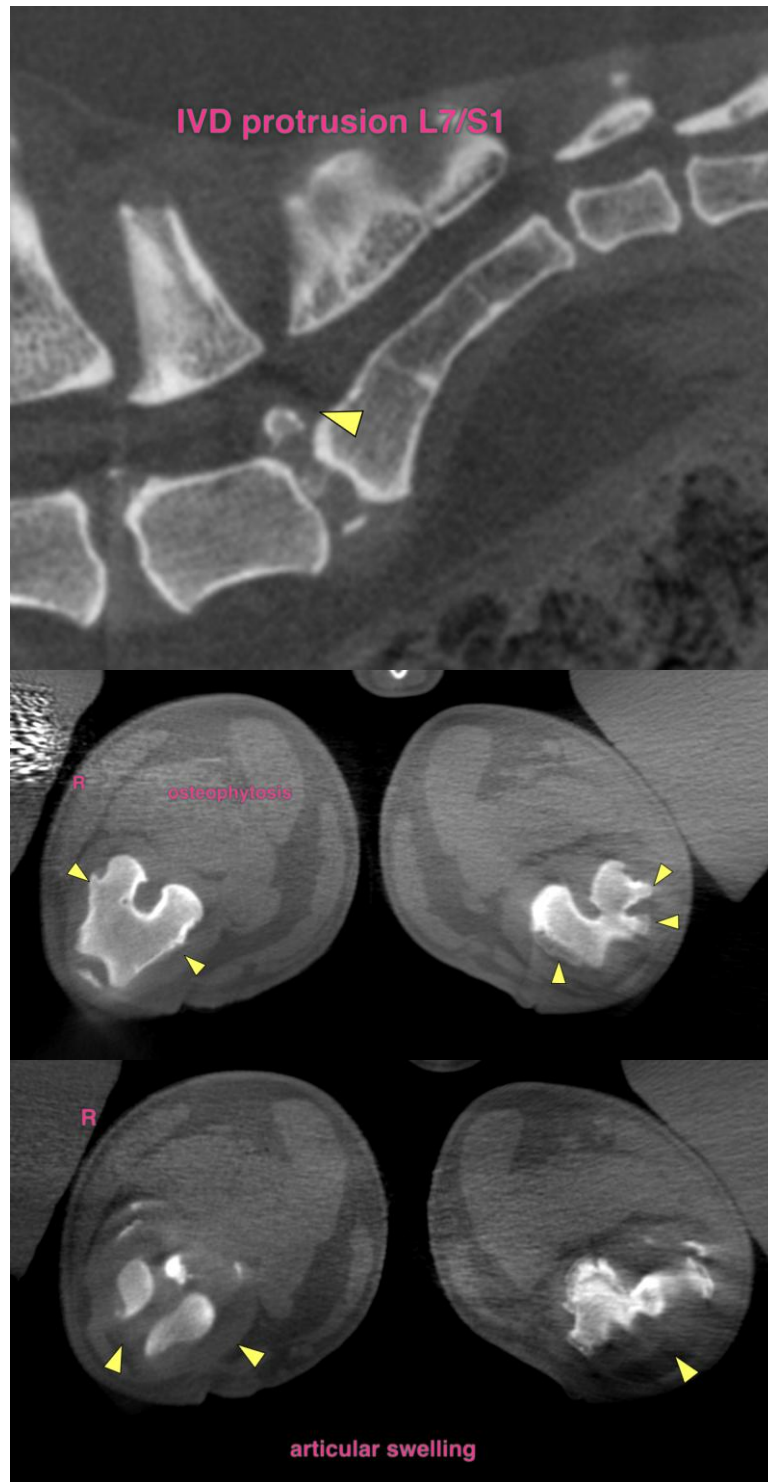
Dr. Vitale

INVOICE

74569

DATE

4-13-26





PATIENT

Macy Scalf

SPECIES

Canine

BREED

Shar Pei Mix

SEX

Female Spayed

AGE

4Y, 4M

WEIGHT

67lbs

INTERPRETED BY

Sebastian Schaub, DVM
Dr. med. vet.
DipECVDI

IMAGING PERFORMED BY

Dr. Burge

HOSPITAL NAME

Wilson Veterinary
Hospital

REFERRING VET

Dr. Vitale

INVOICE

74569

DATE

4-13-26

The information and recommendations provided are based on the images presented by the referring veterinarian/sonographer. No evaluation can be communicated regarding pathology that was not visible in the image/video clips provided.

Thank you for this referral. If the clinical or image interpretation does not parallel your findings or if I can be of any further assistance please contact me.

Sebastian Schaub, Sebastian Schaub, DVM, Dr. med. vet. DipECVDI
info@sonopath.com