



PATIENT

Lucy Marais

SPECIES

Canine

BREED

Poodle

SEX

FN

AGE

8

WEIGHT

8

INTERPRETED BY

Sebastian Schaub, DVM
Dr. med. vet.
DipECVDI

IMAGING PERFORMED BY

Eamon

HOSPITAL NAME

Belconnen Veterinary
Centre

REFERRING VET

Eamon

INVOICE

74572

DATE

4-13-26

PRESENTING CLINICAL SIGNS

dysuria suspect bladder mass
Abnormal PE/Chem/CBC/UA Results: cbc/chem akp elevation

COMPUTED TOMOGRAPHY OF THE THORAX AND ABDOMEN

A pre- and post-contrast CT study of the thorax and abdomen in a bone, lung and soft tissue reconstruction is provided for review.

COMPUTED TOMOGRAPHIC FINDINGS

Thorax

The bony and surrounding soft tissue structures are within normal limits.

The sternal, cranial mediastinal and tracheobronchial lymph nodes are small elongated with a normal short-to-long-axis-ratio is < 0.5, the attenuation and contrast enhancement pattern is uniform and considered within normal limits.

The cardiovascular structures including the pulmonary vasculature are within normal limits.

The bronchial tree presents with regular branching and tapers uniformly towards the periphery as expected, the bronchial walls are thin and smooth. The bronchus-to-artery ratio is within normal limits.

The lung parenchyma presents the expected architecture and attenuation behavior with randomly distributed interspersed punctuate mineralization.

Small incidental gas pockets are seen within the esophageal lumen; there is no evidence of abnormal dilation.

Abdomen

The serosal fat presents normal attenuation behavior. There is no evidence of peritoneal effusion or peritonitis.

Both kidneys present within normal limits for size, shape and organ architecture. After contrast administration multiple small (<2 mm) roundish parenchymal filling defects are seen throughout the renal cortex. The urinary bladder is moderately distended. The urinary bladder wall is smooth and thin. The urethra is not dilated and presents the expected course.

Originating from the right adrenal gland, a well-defined, ovoid shape, uniform soft tissue attenuating and mild irregular contrast enhancing mass is seen; measuring 2.8 x 2.8 x 3.7 cm. The right adrenal mass shows broad contact with the caudal vena cava at the same level; post contrast administration, in the pre-hepatic segment of the caudal vena cava, level with the adrenal mass an intraluminal filling defect is seen – occupying approximately up to 60% of the cross-sectional area of the caudal vena cava at the same level.

Nodular enlargement of the left adrenal gland is appreciated; measuring up to 11 mm in diameter.

Both liver and spleen present with normal shape, even surface, uniformly attenuating parenchyma and homogeneous contrast enhancement, unremarkable.

The pancreas is evenly contoured; the pancreatic parenchyma is homogeneous and presents uniform contrast enhancement.

The position, delineation, wall and content of the gastrointestinal tract are considered within normal limits throughout.



PATIENT

Lucy Marais

SPECIES

Canine

BREED

Poodle

SEX

FN

AGE

8

WEIGHT

8

INTERPRETED BY

Sebastian Schaub, DVM
Dr. med. vet.
DipECVDI

IMAGING PERFORMED BY

Eamon

HOSPITAL NAME

Belconnen Veterinary
Centre

REFERRING VET

Eamon

INVOICE

74572

DATE

4-13-26

The bony and surrounding soft tissue structures reveal no abnormalities.

COMPUTED TOMOGRAPHIC DIAGNOSIS

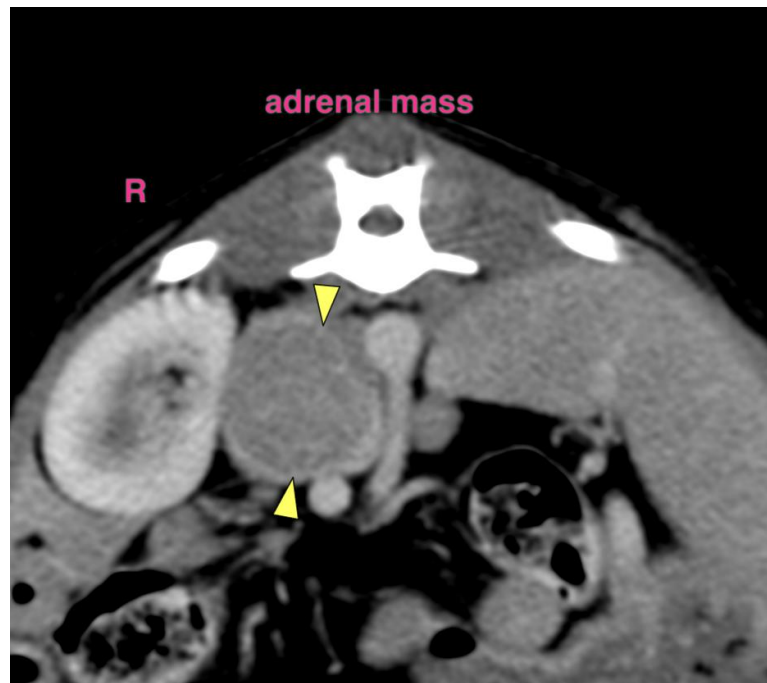
- Right adrenal soft tissue mass with vascular invasion
- Left sided adrenomegaly without vascular invasion
- Pulmonary osteomas
- Multiple simple renal cortical cysts
- No evidence of pulmonary metastatic disease
- Normal upper and lower urinary tract

INTERPRETATION OF THE FINDINGS & FURTHER RECOMMENDATIONS

The right adrenal soft tissue mass is consistent with (non)functional primary adrenal soft tissue neoplasia – such as adenocarcinoma or pheochromocytoma. Surgical management, including venotomy, may be feasible.

The left adrenal enlargement can present (non)functional adrenal nodular hyperplasia or less likely neoplastic transformation (e.g. adenoma, adenocarcinoma, adenocarcinoma).

No abnormalities are appreciated that do explain the dysuria – I do not see evidence of a bladder mass or urethral mass.





PATIENT

Lucy Marais

SPECIES

Canine

BREED

Poodle

SEX

FN

AGE

8

WEIGHT

8

INTERPRETED BY

Sebastian Schaub, DVM
Dr. med. vet.
DipECVDI

IMAGING PERFORMED BY

Eamon

HOSPITAL NAME

Belconnen Veterinary
Centre

REFERRING VET

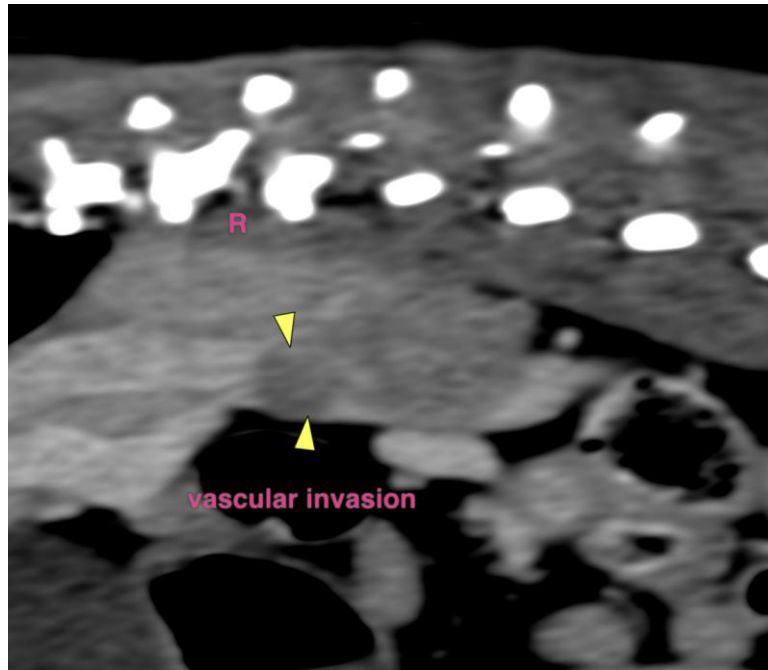
Eamon

INVOICE

74572

DATE

4-13-26



The information and recommendations provided are based on the images presented by the referring veterinarian/sonographer. No evaluation can be communicated regarding pathology that was not visible in the image/video clips provided.

Thank you for this referral. If the clinical or image interpretation does not parallel your findings or if I can be of any further assistance please contact me.

Sebastian Schaub, Sebastian Schaub, DVM, Dr. med. vet. DipECVDI
info@sonopath.com