



PATIENT PRESENTING CLINICAL SIGNS

Rocky Parobczyk O noticed limping started 2 weeks ago, thought it may have been due to stairs but no specific cause seen.

Abnormal PE/Chem/CBC/UA Results: No abnormal PE or BW. Concern for lesion at proximal humerus seen on radiograph

SPECIES

Canine

RADIOGRAPHIC STUDY OF THE SHOULDER JOINTS

Radiographs of the shoulder joints in a mediolateral projection are provided for review.

BREED

RADIOGRAPHIC FINDINGS

Rottweiler

Superimposed on the tuberculum majus of the left shoulder joint, a zone with granular mineralization is appreciated. The osseous margins of the periarticular bones of the left shoulder joint are smooth. Cranial to the left scapular neck, a well-defined, ovoid shaped mineralized body is seen, measuring 7 x 6 mm.

SEX

Male

The osseous and soft tissue structures of the right stifle joint present without abnormalities.

Lamellar new bone formation is seen along the mid diaphysis of the humerus bilaterally – considered as the enthesis of the pectoral muscle.

AGE

RADIOGRAPHIC DIAGNOSIS

8 Years, 2 Months

- Suspect calcifying tendinopathy tendon left supraspinatus muscle
- Dystrophic mineralization soft tissues cranial to the left scapular neck
- Normal right shoulder joint

INTERPRETED BY

Sebastian Schaub, DVM
Dr. med. vet. DipECVDI

INTERPRETATION OF THE FINDINGS & FURTHER RECOMMENDATIONS

HOSPITAL NAME

POCONO PEAK
VETERINARY
CENTER

The current radiographic study of the shoulder joints presents without signs of an aggressive bone lesion. The appreciated mineral opacity level with the tuberculum majus of the left humerus is suggestive for calcifying tendinopathy of the supraspinatus tendon or less likely exostosis formation of the bicipital groove. An ultrasound examination of the shoulder joint(s) can be used to rule out pathology of the bicipital tendon or rotator cuff injury.

REFERRING VET

Dr. Christine Coyle

INVOICE

57781

DATE

4-13-23



PATIENT

Rocky Parobczyk

SPECIES

Canine

BREED

Rottweiler

SEX

Male

AGE

8 Years, 2 Months

INTERPRETED BY

Sebastian Schaub, DVM
Dr. med. vet. DipECVDI

HOSPITAL NAME

POCONO PEAK
VETERINARY
CENTER

REFERRING VET

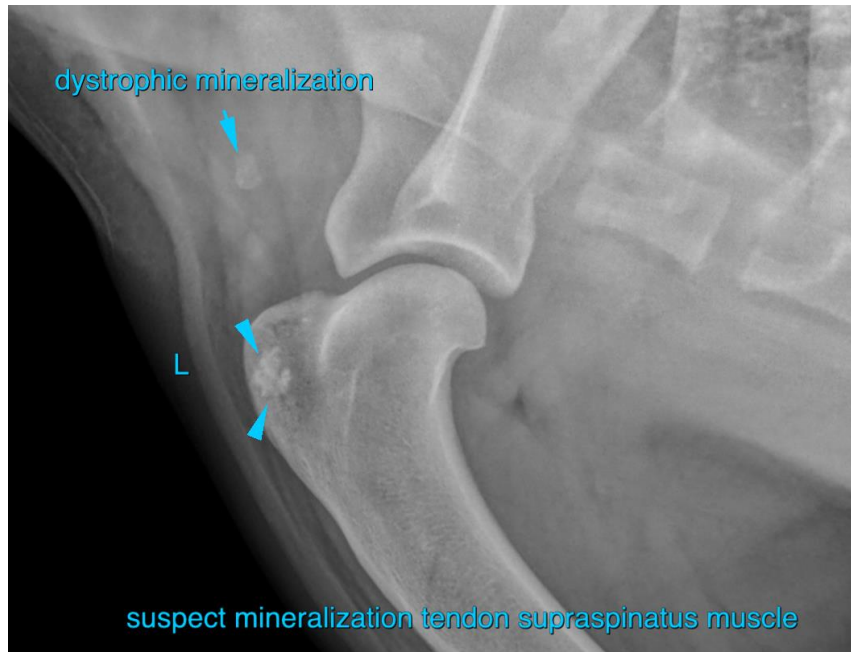
Dr. Christine Coyle

INVOICE

57781

DATE

4-13-23



The information and recommendations provided are based on the images presented by the referring veterinarian/sonographer. No evaluation can be communicated regarding pathology that was not visible in the image/video clips provided.

Thank you for this referral. If the clinical or image interpretation does not parallel your findings or if I can be of any further assistance please contact me.

Sebastian Schaub, Sebastian Schaub, DVM, Dr. med. vet. DipECVDI
sebast.schaub@gmail.com