



PATIENT PRESENTING CLINICAL SIGNS

Pete Byers On Sunday Pete was running full speed and tumbled and yelped and then started to limp on his L hind. Abnormal PE/Chem/CBC/UA Results: TOE TOUCHING ON L HIND DISCOMFORT TO EXTENSION OF L STIFLE DISCOMFORT TO EXTENSION OF L HIP

SPECIES RADIOGRAPHIC STUDY OF THE PELVIS AND STIFLE JOINTS

Canine A complete set of radiographs of the pelvis and the stiffler joints is provided for review.

RADIOGRAPHIC FINDINGS

BREED
Goldendoodle The osseous and surrounding soft tissue structures of the pelvis are within normal limits. Both coxofemoral joints present smooth osseous margins and congruent joint spaces.

The periarticular bones of the left stiffler joint present mild osteophyte new bone formation and a moderate intracapsular soft tissue swelling of the left stiffler joint is appreciated. Mild cranial subluxation of the left tibia is seen.

SEX
Male Neutered The periarticular bones of the right stiffler joint present smooth osseous margins and no sign for intracapsular soft tissue swelling is noted.

AGE RADIOGRAPHIC DIAGNOSIS

6 Years, 6 Months

- Mild degenerative osteoarthritis left stiffler joint
- Articular swelling left stiffler joint
- Mild cranial subluxation left tibia
- Normal right stiffler joint
- Normal pelvis

INTERPRETED BY

Sebastian Schaub, DVM
Dr. med. vet. DipECVDI

INTERPRETATION OF THE FINDINGS & FURTHER RECOMMENDATIONS

HOSPITAL NAME

Elizabeth Animal
Hospital

The mild degenerative changes of the left stiffler joint in combination with the joint effusion and mild cranial tibial subluxation are highly suggestive for underlying failure of the cranial cruciate ligament ± meniscal pathology.

A positive drawer sign or tibial compression test under general anesthesia can be used to confirm the diagnosis.

REFERRING VET

Kim Allyn, DVM

INVOICE

57787

DATE

4-13-23



PATIENT

Pete Byers

SPECIES

Canine

BREED

Goldendoodle

SEX

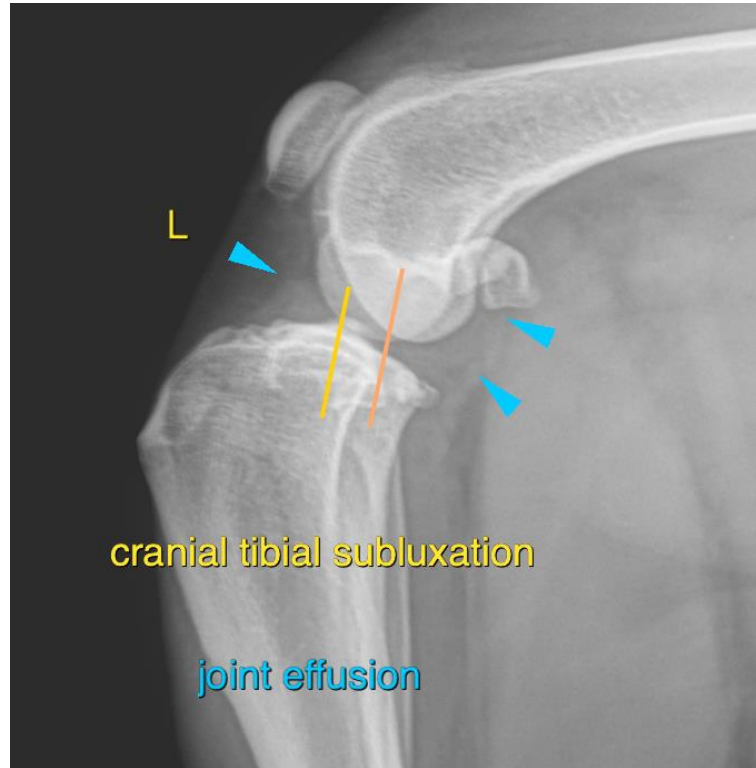
Male Neutered

AGE

6 Years, 6 Months

INTERPRETED BY

Sebastian Schaub, DVM
Dr. med. vet. DipECVDI



HOSPITAL NAME

Elizabeth Animal
Hospital

REFERRING VET

Kim Allyn, DVM

The information and recommendations provided are based on the images presented by the referring veterinarian/sonographer. No evaluation can be communicated regarding pathology that was not visible in the image/video clips provided.

Thank you for this referral. If the clinical or image interpretation does not parallel your findings or if I can be of any further assistance please contact me.

Sebastian Schaub, Sebastian Schaub, DVM, Dr. med. vet. DipECVDI
sebast.schaub@gmail.com

INVOICE

57787

DATE

4-13-23