



PATIENT

Hanna Lafond

PRESENTING CLINICAL SIGNS

Got loose for about 1 week before Animal Control could help catch her; was caught 3 days prior. Is now very skittish. Is eating and drinking well. Client has not found any stool in the yard which is the presenting complaint.

SPECIES

Canine

Abnormal PE/Chem/CBC/UA Results: Abdominal splinting which could be from anxiety. Blood panel and urine submitted.

BREED

Beagle

RADIOGRAPHIC STUDY OF THE ABDOMEN

Radiographs of the abdomen in two imaging planes are provided for review.

SEX

Female Spayed

RADIOGRAPHIC FINDINGS

The surrounding bony structures are within normal limits.

No abnormalities of the extraabdominal soft tissues are noted. The abdominal wall is smooth and thin.

AGE

2 Years

The serosal detail is maintained throughout the peritoneal and retroperitoneal space.

The liver is appropriate in position, size and presents uniform opacity.

The splenic head is in the anticipated position and within normal limits for size and opacity. The splenic body and tail are considered normal for position, size, shape and opacity.

INTERPRETED BY

Sebastian Schaub, DVM
Dr. med. vet. DipECVDI

Both kidneys are seen and present with normal size, shape, delineation and opacity. The urinary bladder is in its anticipated position. No radiopaque calculi are noted throughout the upper and lower urinary tract.

HOSPITAL NAME

Russ LaPierre

The stomach is in its anticipated position and empty.

The small intestinal loops are of even diameter and non-dilated, a small amount of gas is seen within the small intestinal loops and considered within normal limits.

REFERRING VET

Russ LaPierre

The colon is seen in the expected position and presents with appropriate content.

RADIOGRAPHIC DIAGNOSIS

- Normal abdomen

INVOICE

51518

INTERPRETATION OF THE FINDINGS & FURTHER RECOMMENDATIONS

The radiographic study of the abdomen presents without abnormalities. The colon contains a normal amount of fecal material, there are no signs for constipation.

DATE

4-13-22



PATIENT

Hanna Lafond

SPECIES

Canine

BREED

Beagle

SEX

Female Spayed

AGE

2 Years

INTERPRETED BY

Sebastian Schaub, DVM
Dr. med. vet. DipECVDI

HOSPITAL NAME

Russ LaPierre

REFERRING VET

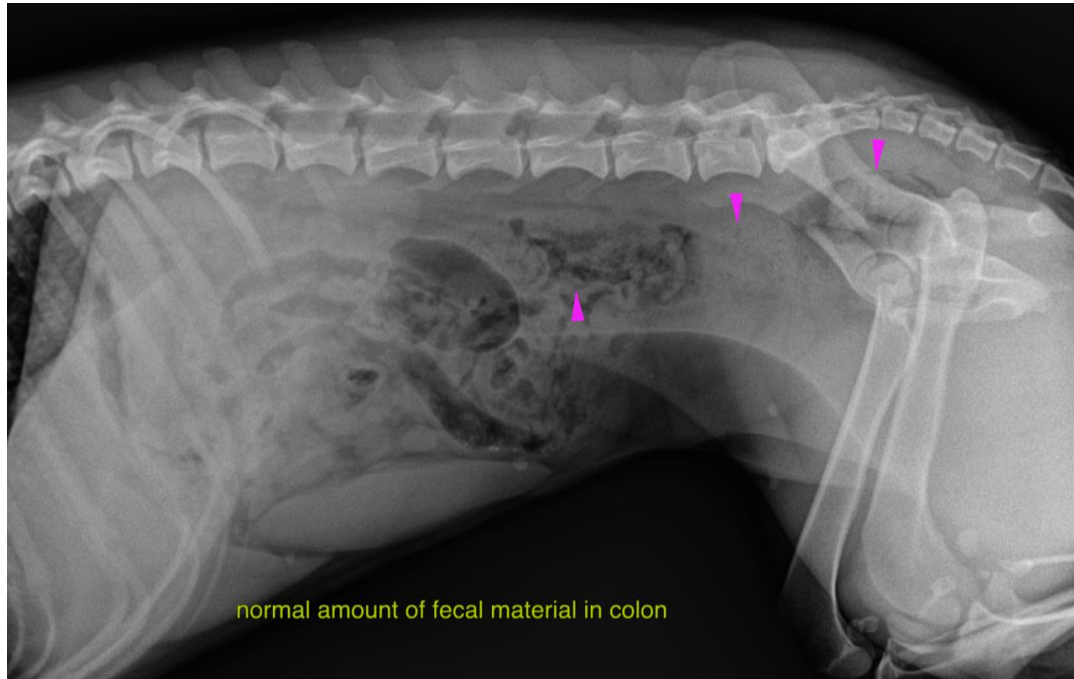
Russ LaPierre

INVOICE

51518

DATE

4-13-22



The information and recommendations provided are based on the images presented by the referring veterinarian/sonographer. No evaluation can be communicated regarding pathology that was not visible in the image/video clips provided.

Thank you for this referral. If the clinical or image interpretation does not parallel your findings or if I can be of any further assistance please contact me.

Sebastian Schaub, Sebastian Schaub, DVM, Dr. med. vet. DipECVDI
sebast.schaub@gmail.com