



PATIENT

Comet NMDOG

PRESENTING CLINICAL SIGNS

P was seen for an emergency for having a mallet in the head.

SPECIES

Canine

COMPUTED TOMOGRAPHY OF THE SKULL

A high resolution pre- and post-contrast CT study of the skull is provided for review.

BREED

Pit Bull

COMPUTED TOMOGRAPHIC FINDINGS

Triadan 305&405 are absent.

SEX

MN

The caudodorsal osseous lamina of the left frontal sinus presents with multiple well-defined fracture lines and small isolated osseous fragments, extending caudally up into the Bregma. The cutaneous surface at the same level is irregular. No perforation of the cranial fossa is appreciated.

The nasal cavity presents the expected aerated spaces between thin & even conchae and turbinates with smooth mucosal lining.

AGE

5 Years

Both temporomandibular joints present congruent joint spaces with even subchondral bone surfaces and are considered within normal limits.

Both tympanic bullae are aerated, the mucosal lining is not seen, the bony wall is smooth and thin. The external ear canals are within normal limits.

INTERPRETED BY

Sebastian Schaub, DVM
Dr. med. vet. DipECVDI

The brain presents no deviation from normal anatomy and symmetry. The brain parenchyma is homogeneous and within normal limits for attenuation and distribution of contrast enhancement. The ventricular system is non-dilated and symmetric.

HOSPITAL NAME

Petroglyph Animal
Hospital

The submandibular and medial retropharyngeal lymph nodes are small and elongated with a normal short-to-long-axis-ratio is < 0.5, the attenuation and contrast enhancement pattern is uniform.

COMPUTED TOMOGRAPHIC DIAGNOSIS

- Acute traumatic fracture caudodorsal aspect of left frontal sinus without significant displacement of the osseous fragments
- Absent triadan 305&405

REFERRING VET

Dr. Raymond Hudgell

INTERPRETATION OF THE FINDINGS & FURTHER RECOMMENDATIONS

INVOICE

51495

The findings are compatible with the history of traumatic insult and secondary fracture of the left frontal bone. No advanced surgical treatment options for the fractured left frontal sinus are warranted.

DATE

4-12-22



PATIENT

Comet NMDOG

SPECIES

Canine

BREED

Pit Bull

SEX

MN

AGE

5 Years

INTERPRETED BY

Sebastian Schaub, DVM
Dr. med. vet. DipECVDI

HOSPITAL NAME

Petroglyph Animal
Hospital

REFERRING VET

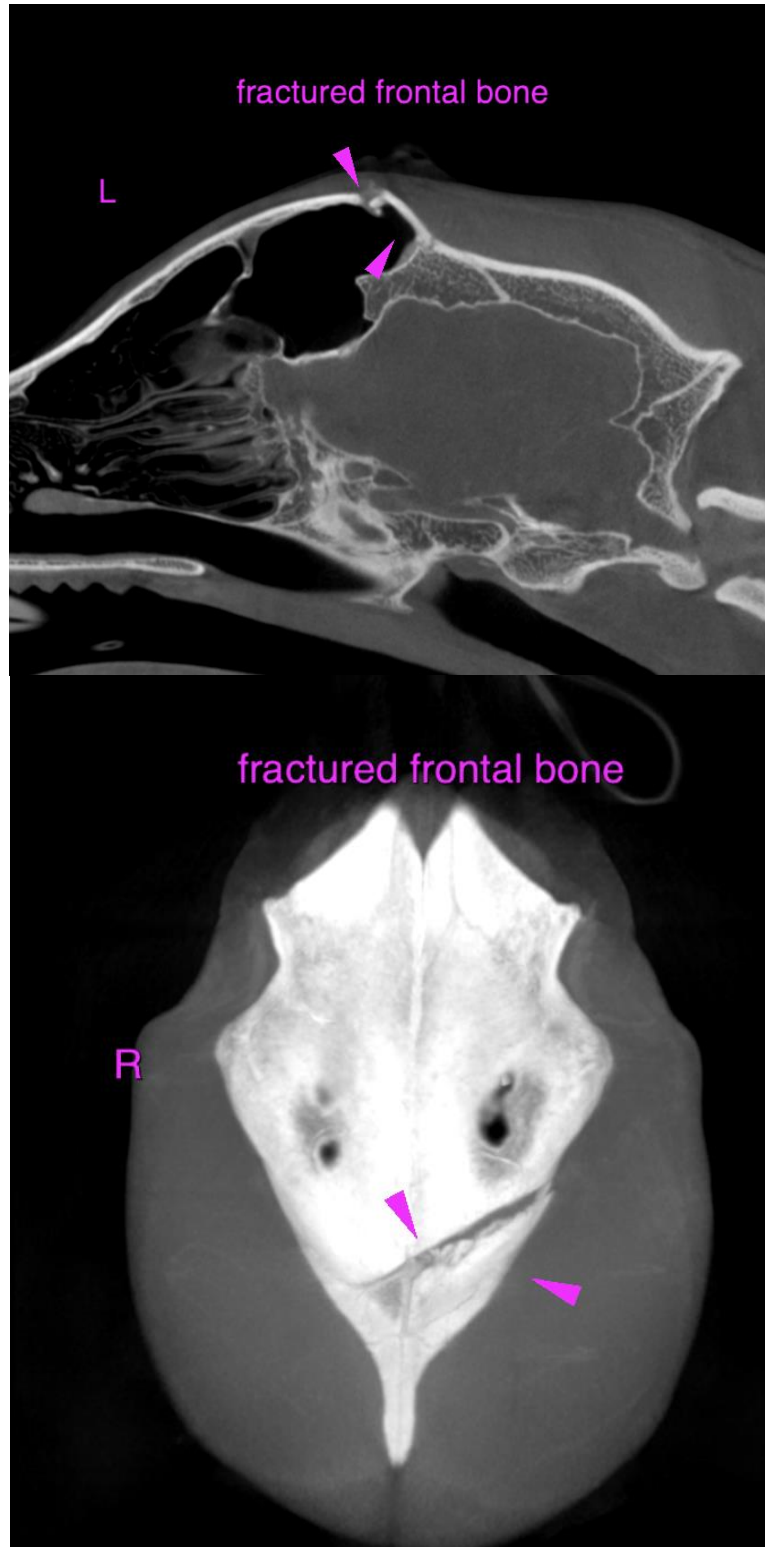
Dr. Raymond Hudgell

INVOICE

51495

DATE

4-12-22





PATIENT

Comet NMDOG

The information and recommendations provided are based on the images presented by the referring veterinarian/sonographer. No evaluation can be communicated regarding pathology that was not visible in the image/video clips provided.

SPECIES

Canine

Thank you for this referral. If the clinical or image interpretation does not parallel your findings or if I can be of any further assistance please contact me.

BREED

Pit Bull

Sebastian Schaub, Sebastian Schaub, DVM, Dr. med. vet. DipECVDI
sebast.schaub@gmail.com

SEX

MN

AGE

5 Years

INTERPRETED BY

Sebastian Schaub, DVM
Dr. med. vet. DipECVDI

HOSPITAL NAME

Petroglyph Animal
Hospital

REFERRING VET

Dr. Raymond Hudgell

INVOICE

51495

DATE

4-12-22