



PATIENT

Coco Tibaldi

PRESENTING CLINICAL SIGNS

Patient presented for hyperesthesia on right neck/shoulder that has been occurring for last few weeks. Pet not jumping as much at home anymore and having some decreased energy. Resistant to dorsal flexion and left extension of cervical spine
Abnormal PE/Chem/CBC/UA Results:

SPECIES

Canine

RADIOGRAPHIC STUDY OF THE CERVICAL SPINE; SHOULDER JOINTS AND ELBOW JOINTS

A complete set of radiographs of the cervical spine and front limbs is provided for review.

BREED

French Bulldog

RADIOGRAPHIC FINDINGS

Mineralized material is superimposed on the intervertebral disc space and ventral aspect of the neuroforamen C2/C3.

SEX

FS

The periarticular bones of both shoulder and elbow joints present smooth osseous margins; no abnormalities of the surrounding soft tissue structures are appreciated.

RADIOGRAPHIC DIAGNOSIS

- Chondroid disc degeneration with potential intervertebral disc protrusion C2/C3
- Normal front limbs bilaterally

AGE

4.5 Years

INTERPRETATION OF THE FINDINGS & FURTHER RECOMMENDATIONS

Discopathy with compressive myelopathy can be a plausible explanation for the presenting clinical signs – however cross-sectional imaging is warranted to confirm the diagnosis and decision making if surgical intervention is an option.

INTERPRETED BY

Sebastian Schaub, DVM
Dr. med. vet. DipECVDI

HOSPITAL NAME

Boca Park Animal
Hospital

No radiographic abnormalities of the front limbs are appreciated.

REFERRING VET

Dr. Corinna Gorgon

INVOICE

51497

DATE

4-12-22



PATIENT

Coco Tibaldi

SPECIES

Canine

BREED

French Bulldog

SEX

FS

AGE

4.5 Years

INTERPRETED BY

Sebastian Schaub, DVM
Dr. med. vet. DipECVDI

HOSPITAL NAME

Boca Park Animal
Hospital

REFERRING VET

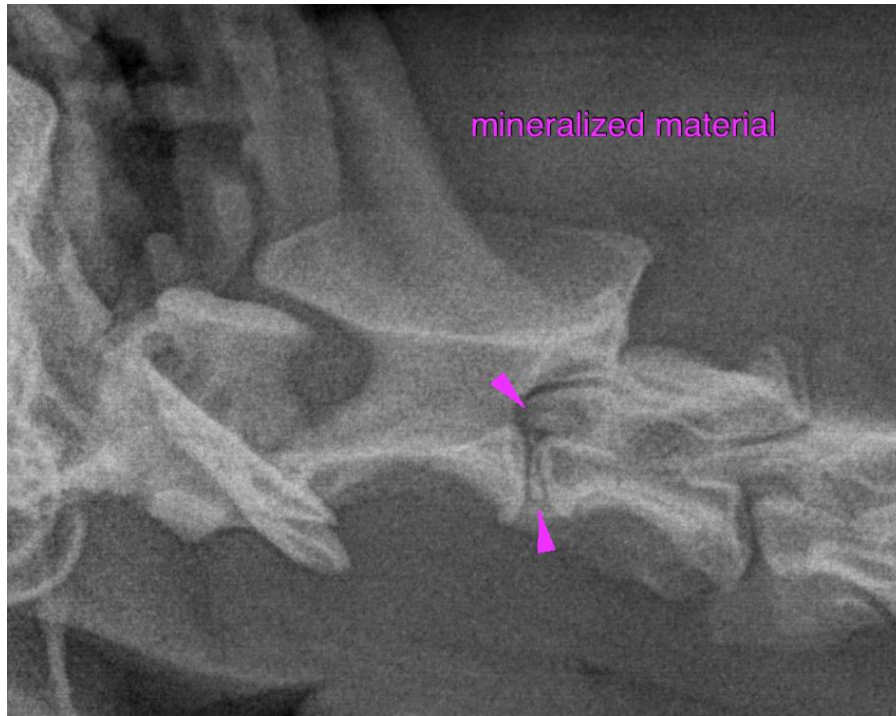
Dr. Corinna Gorgon

INVOICE

51497

DATE

4-12-22



The information and recommendations provided are based on the images presented by the referring veterinarian/sonographer. No evaluation can be communicated regarding pathology that was not visible in the image/video clips provided.

Thank you for this referral. If the clinical or image interpretation does not parallel your findings or if I can be of any further assistance please contact me.

Sebastian Schaub, Sebastian Schaub, DVM, Dr. med. vet. DipECVDI
sebast.schaub@gmail.com