



PATIENT PRESENTING CLINICAL SIGNS

Gracie Cooper Hair loss mainly on hind end-was shaved at previous vet several months ago and fur is not re growing
Abnormal PE/Chem/CBC/UA Results: Concerned for Cushings disease

SPECIES COMPUTED TOMOGRAPHY OF THE THORAX AND ABDOMEN

Canine A high resolution pre- and post-contrast CT study of the abdomen and a plain CT study of the thorax are provided for review.

COMPUTED TOMOGRAPHIC FINDINGS

BREED
Thorax

Bluetick Coonhound The vertebral endplates C5/C6 present moderate spondylosis formation. The left 6th and 7th rib present a non-displaced transverse fracture in the distal third, with solid smooth callus formation.

SEX The sternal, cranial mediastinal and tracheobronchial lymph nodes are small elongated with a normal short-to-long-axis-ratio is < 0.5, the attenuation pattern is uniform.

Female Spayed The cardiovascular structures including the pulmonary vasculature are within normal limits.

AGE The bronchial tree presents with regular branching and tapers uniformly towards the periphery as expected, the bronchial walls are thin and smooth. The bronchus-to-artery ratio is within normal limits.

9 Years, 10 Months The lung parenchyma presents the expected architecture and attenuation behavior.

INTERPRETED BY Small incidental gas pockets are seen within the esophageal lumen, there is no evidence of abnormal dilation.

Sebastian Schaub, DVM
Dr. med. vet. DipECVDI

Abdomen

The serosal fat presents normal attenuation behavior. There is no evidence of peritoneal effusion or peritonitis.

HOSPITAL NAME

Catskill Veterinary Services, PLLC

Both kidneys present within normal limits for size, shape and organ architecture. After contrast administration a bilaterally symmetric and uniform nephro- and pyelogram is noted.

The adrenal glands are within normal limits for size, shape and organ architecture, the maximum cross-sectional diameter of the adrenal glands is <5.5 mm.

REFERRING VET

Dr. Sarah Wright

Both liver and spleen present with normal shape, even surface, uniformly attenuating parenchyma and homogeneous contrast enhancement, unremarkable.

The spleen is prominent and has rounded margins. The splenic parenchyma has a mild irregular contrast enhancement pattern.

INVOICE

57741

The pancreas is evenly contoured, the pancreatic parenchyma is homogeneous and presents uniform contrast enhancement.

The position, delineation, wall and content of the gastrointestinal tract are considered within normal limits throughout.

DATE

4-11-23

The vertebral endplates of the lumbosacral junction present moderate spondylosis formation. Mild central mineralization of the intervertebral discs L3/L4 and L4/L5 is noted.



PATIENT At the caudodorsal aspect of the right gluteus medius muscle, a well-defined lipoma is appreciated.

Gracie Cooper

COMPUTED TOMOGRAPHIC DIAGNOSIS

SPECIES

Canine

- Mild splenomegaly
- Chronic costal fracture 6th&7th left rib – fractures are in the reparation phase
- Lipoma caudal aspect right gluteus medius muscle
- Spondylosis deformans

BREED

Bluetick Coonhound

INTERPRETATION OF THE FINDINGS & FURTHER RECOMMENDATIONS

The mild splenomegaly can be accentuated by general anesthesia with pooling of blood within the spleen. Differentials include nodular hyperplasia, extramedullary hematopoiesis or less likely splenitis or diffuse neoplastic infiltration. In case of doubt, recommend ultrasound guided FNA sampling of the spleen.

SEX

Female Spayed

The adrenal glands present without abnormalities, there are no signs for hyperplasia. However, testing of the pituitary adrenal-axis is warranted to rule out hyperadrenocorticism entirely.

AGE

9 Years, 10 Months

INTERPRETED BY

Sebastian Schaub, DVM
Dr. med. vet. DipECVDI

HOSPITAL NAME

Catskill Veterinary
Services, PLLC

REFERRING VET

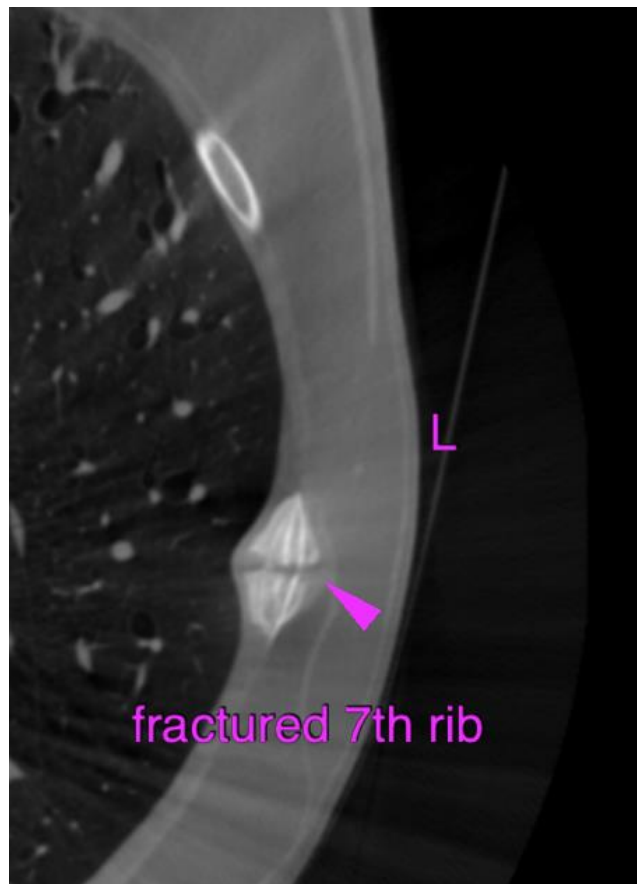
Dr. Sarah Wright

INVOICE

57741

DATE

4-11-23





PATIENT

Gracie Cooper

SPECIES

Canine

BREED

Bluetick Coonhound

SEX

Female Spayed

AGE

9 Years, 10 Months

INTERPRETED BY

Sebastian Schaub, DVM
Dr. med. vet. DipECVDI

HOSPITAL NAME

Catskill Veterinary
Services, PLLC

REFERRING VET

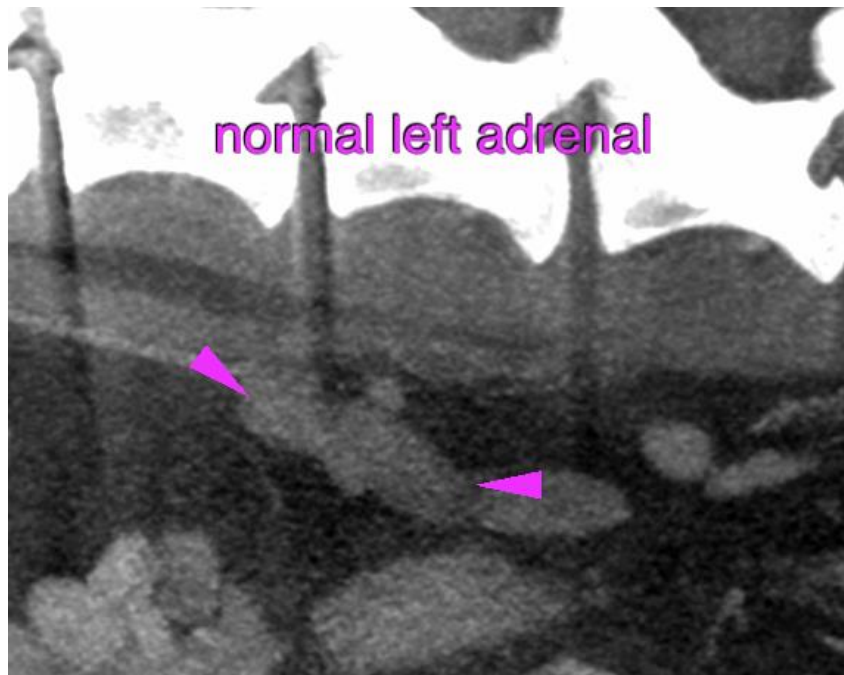
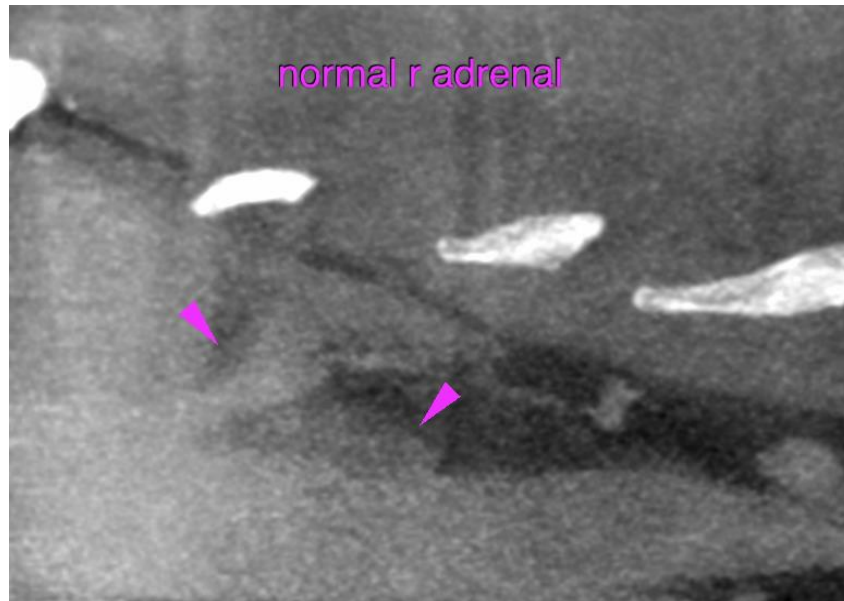
Dr. Sarah Wright

INVOICE

57741

DATE

4-11-23





PATIENT

Gracie Cooper

The information and recommendations provided are based on the images presented by the referring veterinarian/sonographer. No evaluation can be communicated regarding pathology that was not visible in the image/video clips provided.

SPECIES

Canine

Thank you for this referral. If the clinical or image interpretation does not parallel your findings or if I can be of any further assistance please contact me.

Sebastian Schaub, Sebastian Schaub, DVM, Dr. med. vet. DipECVDI
sebast.schaub@gmail.com

BREED

Bluetick Coonhound

SEX

Female Spayed

AGE

9 Years, 10 Months

INTERPRETED BY

Sebastian Schaub, DVM
Dr. med. vet. DipECVDI

HOSPITAL NAME

Catskill Veterinary
Services, PLLC

REFERRING VET

Dr. Sarah Wright

INVOICE

57741

DATE

4-11-23