



PATIENT PRESENTING CLINICAL SIGNS

Chloe Gotthart History of left-sided facial drooping, absent palpebral and menace, facial nerve paralysis. Suspect vestibular disease.

SPECIES COMPUTED TOMOGRAPHY OF THE SKULL

Canine A high resolution pre- and post-contrast CT study of the skull is provided for review.

COMPUTED TOMOGRAPHIC FINDINGS

BREED The tooth elements 105, 305, 311, 405, 410 and 411 are absent.

French Bulldog The nasal cavity presents the expected aerated spaces between thin & even conchae and turbinates with smooth mucosal lining. The soft palate is mildly thickened.

SEX Both temporomandibular joints present congruent joint spaces with even subchondral bone surfaces and are considered within normal limits.

FS The left tympanic bulla is filled with non-contrast enhancing soft tissue material. The wall of the left tympanic bulla is prominent and smooth. The wall of the left external ear canal is mildly thickened and the lumen is narrowed. The right external ear canal and right tympanic bulla are within normal limits.

AGE The brain presents no deviation from normal anatomy and symmetry. The brain parenchyma is homogeneous and within normal limits for attenuation and distribution of contrast enhancement. The ventricular system is non-dilated and symmetric.

4 Years, 3 Months

INTERPRETED BY The submandibular and medial retropharyngeal lymph nodes are small and elongated with a normal short-to-long-axis-ratio is < 0.5, the attenuation and contrast enhancement pattern is uniform.

Sebastian Schaub, DVM
Dr. med. vet. DipECVDI

COMPUTED TOMOGRAPHIC DIAGNOSIS

- Left sided otitis media
- Left sided mild otitis externa
- Thickened soft palate
- Absent triadan 105, 305, 311, 405, 410 and 411

HOSPITAL NAME

Catskill Veterinary Services, PLLC

INTERPRETATION OF THE FINDINGS & FURTHER RECOMMENDATIONS

REFERRING VET The left sided otitis media can be a source for the left sided facial nerve palsy. The otitis media might be a sequela to the left sided otitis externa – if not done so yet, recommend otoscopy to check the integrity of the tympanic membrane. Either myringotomy for sampling and flushing the left middle ear or surgical options might be considered.

Dr. Janis McGill

INVOICE

57738

DATE

4-11-23



PATIENT

Chloe Gotthart

SPECIES

Canine

BREED

French Bulldog

SEX

FS

AGE

4 Years, 3 Months

INTERPRETED BY

Sebastian Schaub, DVM
Dr. med. vet. DipECVDI

HOSPITAL NAME

Catskill Veterinary
Services, PLLC

REFERRING VET

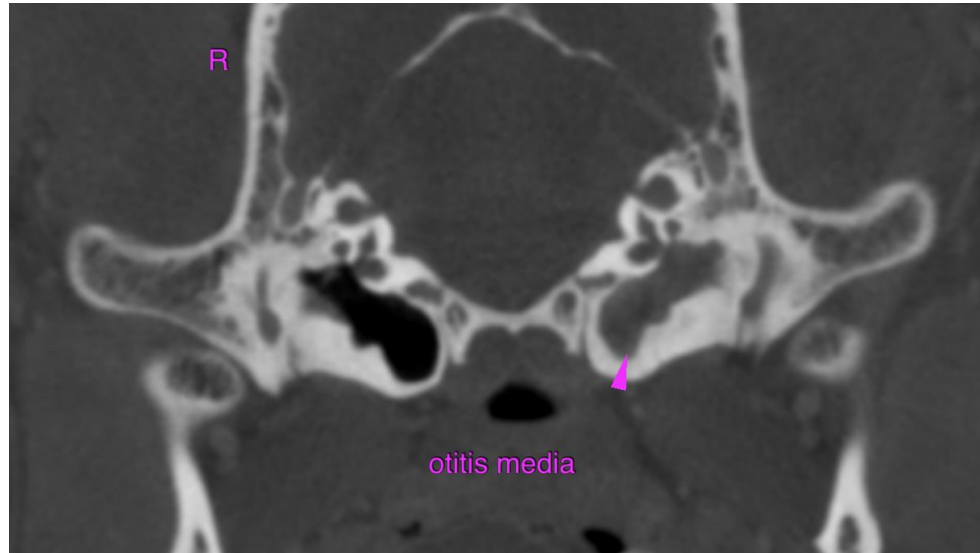
Dr. Janis McGill

INVOICE

57738

DATE

4-11-23



The information and recommendations provided are based on the images presented by the referring veterinarian/sonographer. No evaluation can be communicated regarding pathology that was not visible in the image/video clips provided.

Thank you for this referral. If the clinical or image interpretation does not parallel your findings or if I can be of any further assistance please contact me.

Sebastian Schaub, Sebastian Schaub, DVM, Dr. med. vet. DipECVDI
sebast.schaub@gmail.com