



PATIENT PRESENTING CLINICAL SIGNS

Bode Blair readjusting jaw sometimes, since before 1 year old, lip smacking, grinding teeth sometimes Opening mouth OK, normal range of motion for mandible, no audible noise while mouth is opening/closing r/o any TMJ abnormalities Has couple of teeth with tooth resorption

SPECIES COMPUTED TOMOGRAPHY OF THE SKULL

Feline A high resolution pre- and post-contrast CT study of the skull is provided for review.

COMPUTED TOMOGRAPHIC FINDINGS

BREED
Bengal The pictured parts of the dentition are complete. Triadan 409 presents signs of resorptive lesion at the distal aspect of the crown. Advanced resorption of the crown of triadan 308 is appreciated. The remainder of the dentition present without abnormalities.

SEX
MN The nasal cavity presents the expected aerated spaces between thin & even conchae and turbinates with smooth mucosal lining.

AGE
2 Years Both tympanic bullae are aerated, the mucosal lining is not seen, the bony wall is smooth and thin. The external ear canals are within normal limits.

INTERPRETED BY
Sebastian Schaub, DVM
Dr. med. vet. DipECVDI

COMPUTED TOMOGRAPHIC DIAGNOSIS

- Resorptive dental lesions triadan 308 and 409

HOSPITAL NAME INTERPRETATION OF THE FINDINGS & FURTHER RECOMMENDATIONS

Veterinary Dental Services, LLC Two dental elements can be identified by CT, presenting with resorptive lesions of the crown.

REFERRING VET

Feigin

INVOICE

57742

DATE

4-11-23



PATIENT

Bode Blair

SPECIES

Feline

BREED

Bengal

SEX

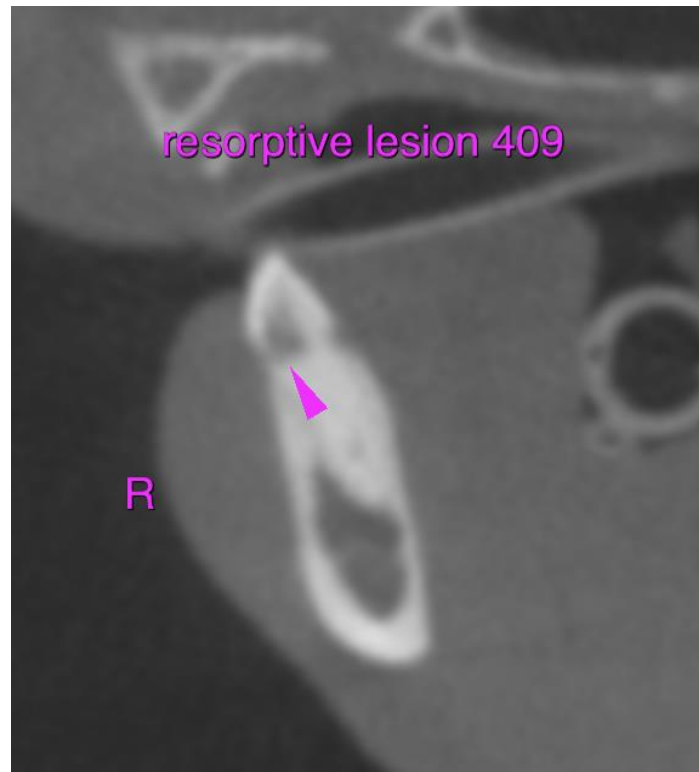MN

AGE

2 Years

INTERPRETED BY

Sebastian Schaub, DVM
Dr. med. vet. DipECVDI



HOSPITAL NAME

Veterinary Dental
Services, LLC

REFERRING VET

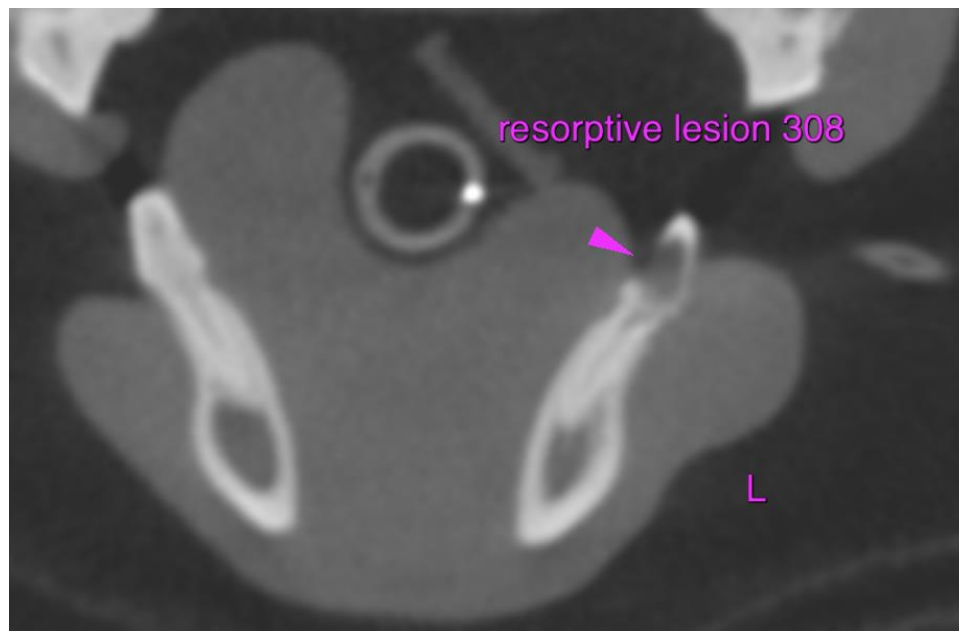
Feigin

INVOICE

57742

DATE

4-11-23





PATIENT

Bode Blair

The information and recommendations provided are based on the images presented by the referring veterinarian/sonographer. No evaluation can be communicated regarding pathology that was not visible in the image/video clips provided.

SPECIES

Feline

Thank you for this referral. If the clinical or image interpretation does not parallel your findings or if I can be of any further assistance please contact me.

BREED

Bengal

Sebastian Schaub, Sebastian Schaub, DVM, Dr. med. vet. DipECVDI
sebast.schaub@gmail.com

SEX

MN

AGE

2 Years

INTERPRETED BY

Sebastian Schaub, DVM
Dr. med. vet. DipECVDI

HOSPITAL NAME

Veterinary Dental
Services, LLC

REFERRING VET

Feigin

INVOICE

57742

DATE

4-11-23