

**PATIENT**

Nala Bailey

PRESENTING CLINICAL SIGNS

Intermittent lameness right hind limb

SPECIES

Canine

RADIOGRAPHIC STUDY OF THE PELVIS & STIFLE JOINTS

A VD view of the pelvis and radiographs of the right stifle joint in two imaging planes are provided for review.

BREED

Pitbull

RADIOGRAPHIC FINDINGS

The periarticular bones of the right coxofemoral joint present mild to moderate osteophyte new bone formation.

The periarticular bones of the left stifle joint present mild osteophyte new bone formation.

SEX

FS

The periarticular bones of the right stifle joint are smooth, there is no evidence of intracapsular soft tissue swelling. The distal segment of the right femur presents a mild coarse trabecular pattern. The region of the insertion of the gastrocnemius muscle is irregular – appears to be bilaterally symmetric.

AGE

9.5 Years

RADIOGRAPHIC DIAGNOSIS

- Degenerative osteoarthritis right coxofemoral joint
- Mild coarse trabecular pattern distal right femur
- Evidence of mild degenerative osteoarthritis left stifle joint

INTERPRETED BY

Sebastian Schaub, DVM
Dr. med. vet. DipECVDI

INTERPRETATION OF THE FINDINGS & FURTHER RECOMMENDATIONS

The degenerative osteoarthritis of the right coxofemoral joint can be a source for lameness. Check if pain can be elicited by manipulation of the coxofemoral joint, supporting the diagnosis.

The mild coarse trabecular pattern of the right distal femur is no specific and can still present normal anatomical variant. However, if pain can be elicited by pressure on the right distal femur, recommend follow up radiographs in 2-4 weeks to check for progressive changes.

HOSPITAL NAME

New Bridge
Veterinary Practice

REFERRING VET

Dr. James Corrao

INVOICE

51460

DATE

4-11-22



PATIENT

Nala Bailey

SPECIES

Canine

BREED

Pitbull

SEX

FS

AGE

9.5 Years

INTERPRETED BY

Sebastian Schaub, DVM
Dr. med. vet. DipECVDI

HOSPITAL NAME

New Bridge
Veterinary Practice

REFERRING VET

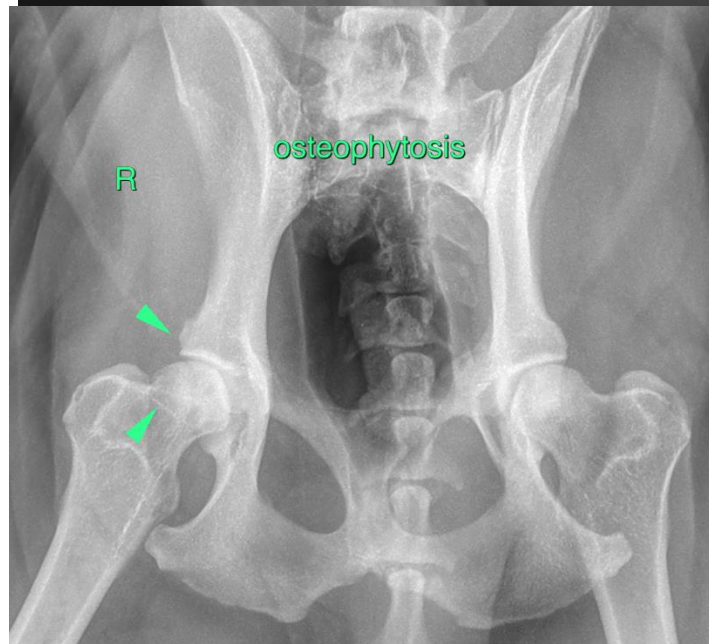
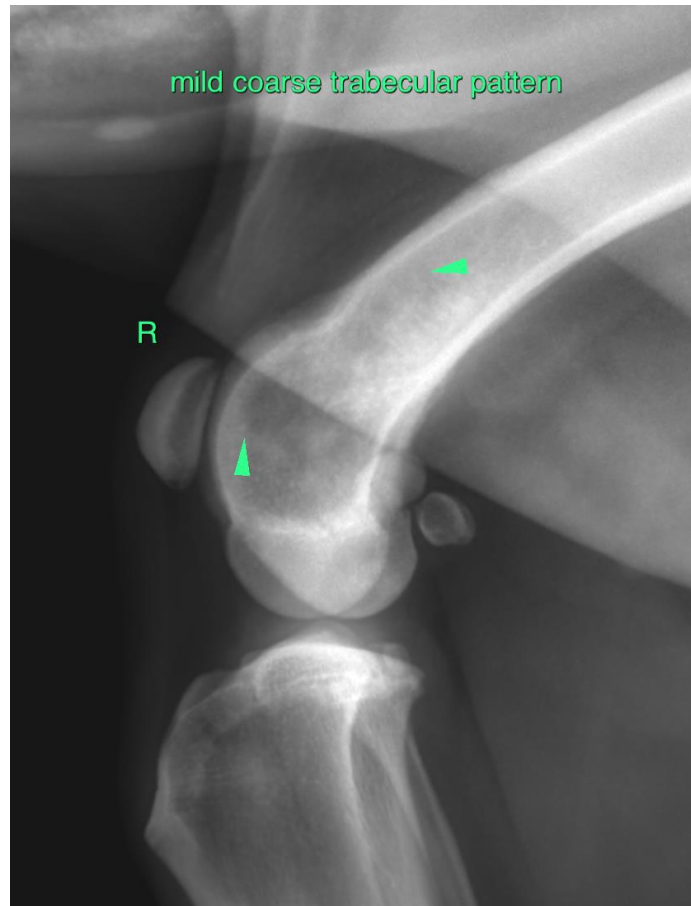
Dr. James Corrao

INVOICE

51460

DATE

4-11-22





PATIENT

Nala Bailey

SPECIES

Canine

The information and recommendations provided are based on the images presented by the referring veterinarian/sonographer. No evaluation can be communicated regarding pathology that was not visible in the image/video clips provided.

BREED

Pitbull

Thank you for this referral. If the clinical or image interpretation does not parallel your findings or if I can be of any further assistance please contact me.

SEX

FS

Sebastian Schaub, Sebastian Schaub, DVM, Dr. med. vet. DipECVDI
sebast.schaub@gmail.com

AGE

9.5 Years

INTERPRETED BY

Sebastian Schaub, DVM
Dr. med. vet. DipECVDI

HOSPITAL NAME

New Bridge
Veterinary Practice

REFERRING VET

Dr. James Corrao

INVOICE

51460

DATE

4-11-22