



PATIENT

Kiwi Aguilar

PRESENTING CLINICAL SIGNS

pet is here for 1 time every 3 day vomiting for a few weeks. Owner does have 2 other cats but the vomit is being found around where this pet hangs out. Owner has not noted any other issues or concerns for pet.

SPECIES

Feline

RADIOGRAPHIC STUDY OF THE ABDOMEN

Radiographs of the abdomen in two imaging planes are provided for review.

BREED

DSH

RADIOGRAPHIC FINDINGS

The surrounding bony structures are within normal limits.

SEX

SF

No abnormalities of the extraabdominal soft tissues are noted. The abdominal wall is smooth and thin.

The serosal detail is maintained throughout the peritoneal and retroperitoneal space.

The liver is appropriate in position, size and presents uniform opacity.

AGE

2 Years, 10 Months

The splenic head is in the anticipated position and within normal limits for size and opacity.

INTERPRETED BY

Sebastian Schaub, DVM
Dr. med. vet. DipECVDI

Both kidneys are seen and present with normal size, shape, delineation and opacity. The urinary bladder is in its anticipated position. No radiopaque calculi are noted throughout the upper and lower urinary tract.

The stomach is in its anticipated position and presents normal content.

HOSPITAL NAME

DPC Veterinary
Hospital

The small intestinal loops are of even diameter and non-dilated, a small amount of gas is seen within the small intestinal loops and considered within normal limits.

The colon is seen in the expected position and presents with appropriate content.

RADIOGRAPHIC DIAGNOSIS

REFERRING VET

Dr. Rivera

- Normal abdomen

INTERPRETATION OF THE FINDINGS & FURTHER RECOMMENDATIONS

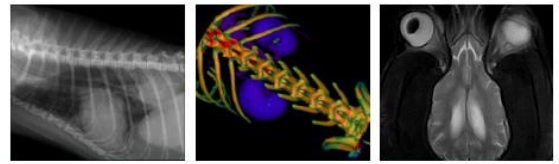
INVOICE

51465

The radiographic study of the abdomen presents without abnormalities explaining the described clinical signs. There is no evidence of radiopaque foreign material or signs for gastrointestinal mechanical obstruction. Consider complementing workup by a complete abdominal ultrasound examination to rule out intramural changes (e.g. inflammatory, neoplastic).

DATE

4-11-22



PATIENT

Kiwi Aguilar

SPECIES

Feline

BREED

DSH

SEX

SF

AGE

2 Years, 10 Months

INTERPRETED BY

Sebastian Schaub, DVM
Dr. med. vet. DipECVDI

HOSPITAL NAME

DPC Veterinary
Hospital

REFERRING VET

Dr. Rivera

INVOICE

51465

DATE

4-11-22

The information and recommendations provided are based on the images presented by the referring veterinarian/sonographer. No evaluation can be communicated regarding pathology that was not visible in the image/video clips provided.

Thank you for this referral. If the clinical or image interpretation does not parallel your findings or if I can be of any further assistance please contact me.

Sebastian Schaub, Sebastian Schaub, DVM, Dr. med. vet. DipECVDI
sebast.schaub@gmail.com