



**PATIENT PRESENTING CLINICAL SIGNS**

Lloyd Hill HBC - L4 Fracture, R Acetabular , L Humeral , Pneumothorax, Poly Trauma and contusions Would like to make sure not missing anything before taking to surgery

**SPECIES COMPUTED TOMOGRAPHY OF THE THORAX**

Canine A high resolution plain CT study of the thorax is provided for review.

**COMPUTED TOMOGRAPHIC FINDINGS**

**BREED** A pleural catheter is entering the right pleural cavity by the 8<sup>th</sup> right intercostal space.

Blue Heeler The growth plates of the osseous structures are age-related open. In the mid diaphysis of the left humerus, an oblique fracture is appreciated with medial and proximal displacement of the distal fragment.

**SEX** A small amount of free gas is appreciated in the pleural cavity. The lung lobes are mildly retracted from the thoracic wall. Gas is dorsally in a non-dependent position, between the right caudal lung lobe and the thoracic wall – likely trapped gas.

Male

The lung parenchyma presents a generalized cloudy ground glass attenuation pattern.

**AGE** Small incidental gas pockets are seen within the esophageal lumen, there is no evidence of abnormal dilation.

4 Months

**INTERPRETED BY**

Sebastian Schaub, DVM  
Dr. med. vet. DipECVDI

**COMPUTED TOMOGRAPHIC DIAGNOSIS**

- Traumatic pneumothorax
- Pulmonary contusion
- History of traumatic acute oblique fracture diaphysis left humerus
- Known Salter Harris Type II fracture caudal vertebral endplate L4 with secondary ventral displacement and step formation between L4/L5 of 4.1 mm and mild rotatory axial deviation of approximately 8°

**HOSPITAL NAME**

Southern Oregon  
Veterinary Specialty  
Center

**INTERPRETATION OF THE FINDINGS & FURTHER RECOMMENDATIONS**

The findings are fitting the history and no additional abnormalities are appreciated. Surgical management of the fractures has already been scheduled.

**REFERRING VET**

Ravi Seshadri

**INVOICE**

57706

**DATE**

4-10-23



**PATIENT**

Lloyd Hill

**SPECIES**

Canine

**BREED**

Blue Heeler

**SEX**

Male

**AGE**

4 Months

**INTERPRETED BY**

Sebastian Schaub, DVM  
Dr. med. vet. DipECVDI

**HOSPITAL NAME**

Southern Oregon  
Veterinary Specialty  
Center

**REFERRING VET**

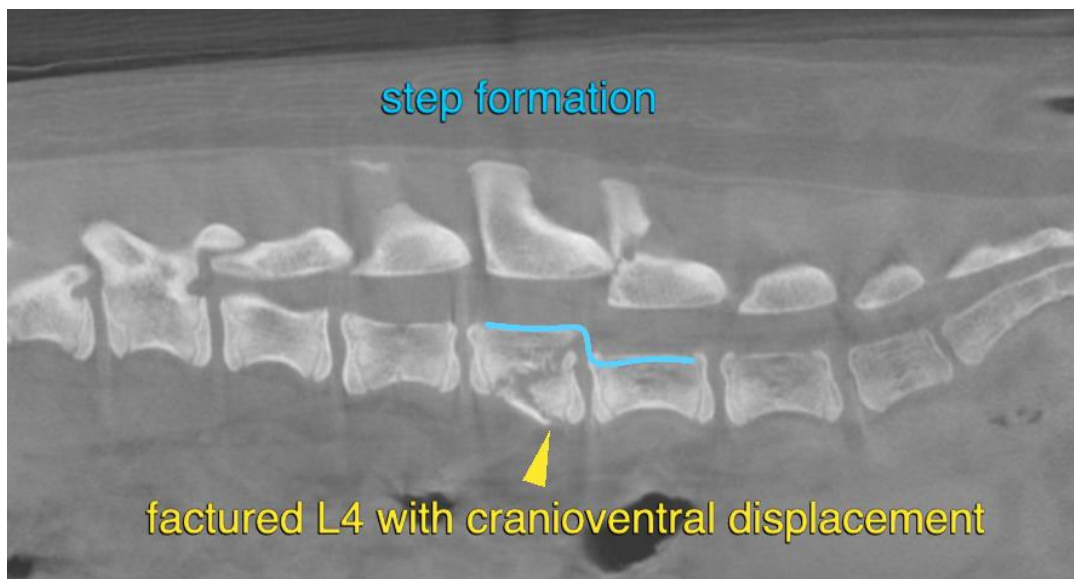
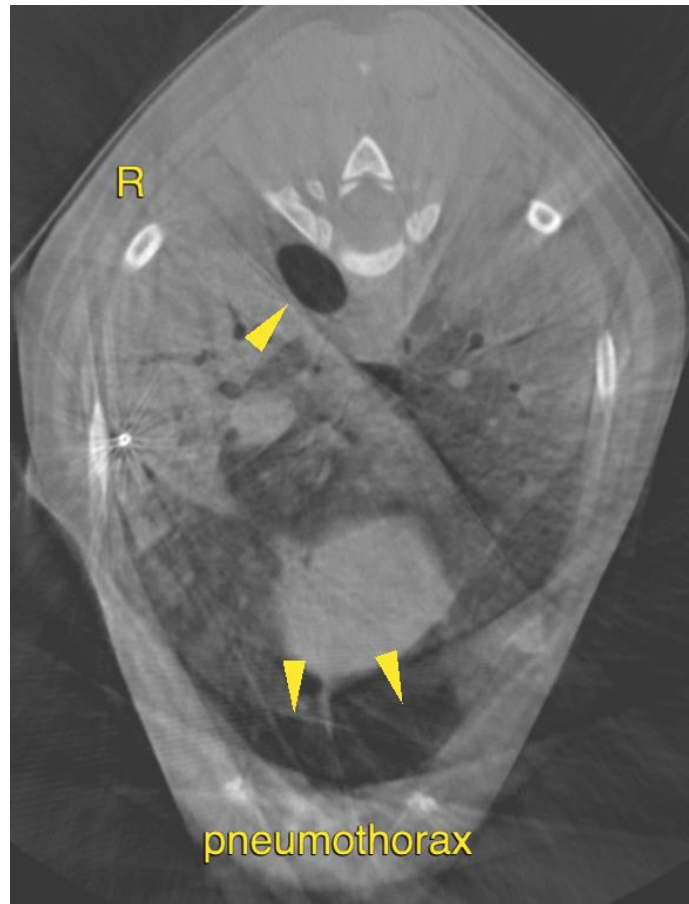
Ravi Seshadri

**INVOICE**

57706

**DATE**

4-10-23





**PATIENT**

Lloyd Hill

**SPECIES**

Canine

The information and recommendations provided are based on the images presented by the referring veterinarian/sonographer. No evaluation can be communicated regarding pathology that was not visible in the image/video clips provided.

**BREED**

Blue Heeler

Thank you for this referral. If the clinical or image interpretation does not parallel your findings or if I can be of any further assistance please contact me.

**Sebastian Schaub**, Sebastian Schaub, DVM, Dr. med. vet. DipECVDI  
sebast.schaub@gmail.com

**SEX**

Male

**AGE**

4 Months

**INTERPRETED BY**

Sebastian Schaub, DVM  
Dr. med. vet. DipECVDI

**HOSPITAL NAME**

Southern Oregon  
Veterinary Specialty  
Center

**REFERRING VET**

Ravi Seshadri

**INVOICE**

57706

**DATE**

4-10-23