



**PATIENT PRESENTING CLINICAL SIGNS**

Lilly Cassarly P presented for severe neck pain, P tumbled down steps about 2 weeks ago, P has progressed and gotten worse, P has jerking movements that are new.

**SPECIES COMPUTED TOMOGRAPHY OF THE SKULL, THORAX AND ABDOMEN**

Canine A high resolution pre- and post-contrast CT study of the neck is provided for review.

**BREED COMPUTED TOMOGRAPHIC FINDINGS**

Chihuahua The foramen magnum has a prominent dorsal notch.  
 The intervertebral disc C2/C3, C4/C5 and C5/C6 are mildly bulging into the vertebral canal, distorting the ventral epidural space at the same level.  
 The vertebral body of T1 presents an ill-defined zone with moderate sclerosis.

**SEX COMPUTED TOMOGRAPHIC DIAGNOSIS**

- FS
- Intervertebral disc protrusion C2/C3, C4/C5 and C5/C6 without compressive myelopathy
  - Keyhole malformation foramen magnum – incidental

**AGE INTERPRETATION OF THE FINDINGS & FURTHER RECOMMENDATIONS**

6 Years The CT study presents without signs of relevant disc disease. However, in case of strong clinical suspicion for underlying compressive myelopathy or intramedullary lesions along the cervical spine, recommend complementing workup by a myelographic CT study or MRI study of the cervical spine.

**INTERPRETED BY**

Sebastian Schaub, DVM  
 Dr. med. vet. DipECVDI

**HOSPITAL NAME**

Animal Emergency  
 Hospital Volusia

**REFERRING VET**

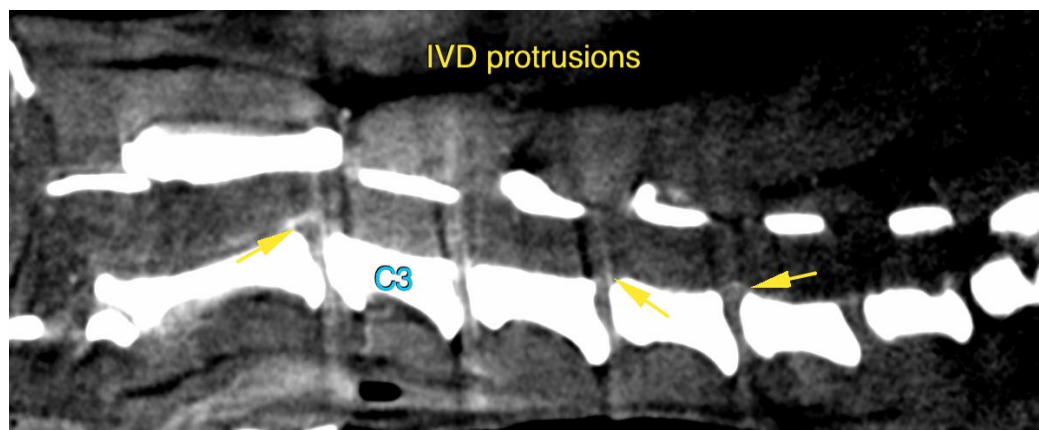
Alyssa Carver

**INVOICE**

57710

**DATE**

4-10-23





**PATIENT**

Lilly Cassarly

The information and recommendations provided are based on the images presented by the referring veterinarian/sonographer. No evaluation can be communicated regarding pathology that was not visible in the image/video clips provided.

**SPECIES**

Canine

Thank you for this referral. If the clinical or image interpretation does not parallel your findings or if I can be of any further assistance please contact me.

**Sebastian Schaub**, Sebastian Schaub, DVM, Dr. med. vet. DipECVDI  
sebast.schaub@gmail.com

**BREED**

Chihuahua

**SEX**

FS

**AGE**

6 Years

**INTERPRETED BY**

Sebastian Schaub, DVM  
Dr. med. vet. DipECVDI

**HOSPITAL NAME**

Animal Emergency  
Hospital Volusia

**REFERRING VET**

Alyssa Carver

**INVOICE**

57710

**DATE**

4-10-23