



PATIENT PRESENTING CLINICAL SIGNS

Belle Pastor Bloody formed stool twice today. No vomiting. Not eating. Was left unattended all day yesterday, was given easter treats as per owner. Has had diarrhea for past few days.
Abnormal PE/Chem/CBC/UA Results: In house bloodwork done today attached.

SPECIES RADIOGRAPHIC STUDY OF THE ABDOMEN

Canine Radiographs of the abdomen in three imaging planes are provided for review.

RADIOGRAPHIC FINDINGS

BREED The surrounding bony structures are within normal limits.

Cockapoo No abnormalities of the extraabdominal soft tissues are noted. The abdominal wall is smooth and thin.
The serosal detail is maintained throughout the peritoneal and retroperitoneal space.

SEX The liver is appropriate in position, size and presents uniform opacity.

Spayed Female The splenic head is in the anticipated position and within normal limits for size and opacity. The splenic body and tail are considered normal for position, size, shape and opacity.

AGE Both kidneys are seen and present with normal size, shape, delineation and opacity. The urinary bladder is in its anticipated position. No radiopaque calculi are noted throughout the upper and lower urinary tract.

8 Months

INTERPRETED BY The stomach is in its anticipated position and presents normal content.

Sebastian Schaub, DVM
Dr. med. vet. DipECVDI

The small intestinal loops are of even diameter and non-dilated, a small amount of chymus, gas is seen within the small intestinal loops and considered within normal limits.

The colon is seen in the expected position and presents with appropriate content.

HOSPITAL NAME RADIOGRAPHIC DIAGNOSIS

Truscott Animal
Hospital

- Alimentary pattern gastrointestinal tract

INTERPRETATION OF THE FINDINGS & FURTHER RECOMMENDATIONS

REFERRING VET The radiographic study of the abdomen presents without relevant abnormalities. There is no evidence of radiopaque foreign material, abnormal gas pattern or signs for gastrointestinal mechanical obstruction. Rule out dysbacteriosis, parasitic infection, dietary indiscretion, other.

Dr. Medhat Meawad

INVOICE

57711

DATE

4-10-23



PATIENT

Belle Pastor

SPECIES

Canine

BREED

Cockapoo

SEX

Spayed Female

AGE

8 Months

INTERPRETED BY

Sebastian Schaub, DVM
Dr. med. vet. DipECVDI

HOSPITAL NAME

Truscott Animal
Hospital

REFERRING VET

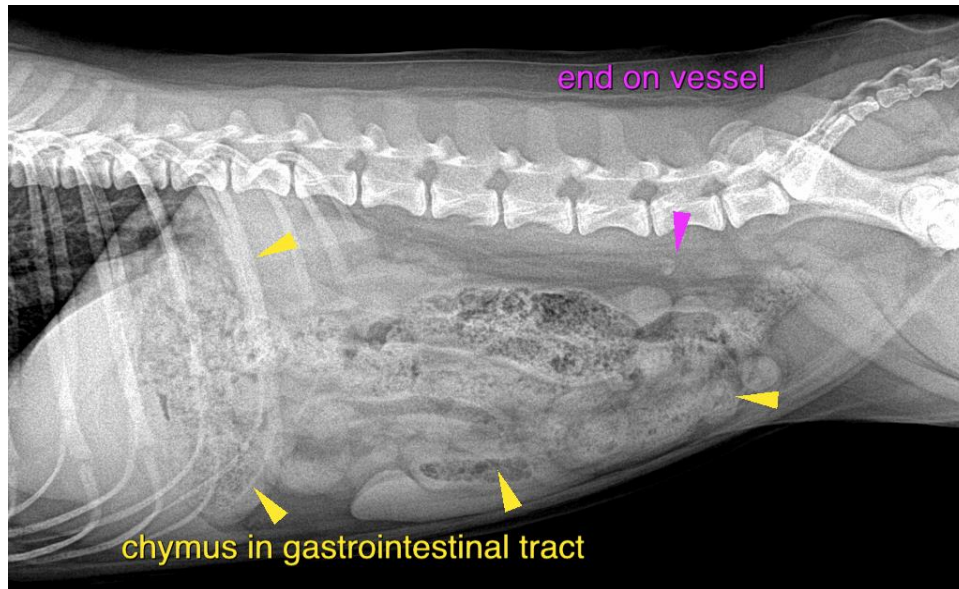
Dr. Medhat Meawad

INVOICE

57711

DATE

4-10-23



The information and recommendations provided are based on the images presented by the referring veterinarian/sonographer. No evaluation can be communicated regarding pathology that was not visible in the image/video clips provided.

Thank you for this referral. If the clinical or image interpretation does not parallel your findings or if I can be of any further assistance please contact me.

Sebastian Schaub, Sebastian Schaub, DVM, Dr. med. vet. DipECVDI
sebast.schaub@gmail.com