



PATIENT

Teddy Petrosino

PRESENTING CLINICAL SIGNS

Pet had an episode last night, O saw pet jump out of cat condo, whining in pain and rubbing himself on floor, moving a lot, since then not wanting to eat, seems disorientated, eyes are very dilated. Not himself, not eating and drinking today is looking around abnormally eyes dilated heart murmur IV/VI tense on abdominal palpation elevated neutrophils

SPECIES

Feline

RADIOGRAPHIC STUDY OF THE THORAX & ABDOMEN

A complete set of radiographs of the thorax and abdomen is provided for review.

BREED

DSH

RADIOGRAPHIC FINDINGS

Thorax

SEX

The surrounding bony structures are within normal limits.

MN

The extrathoracic soft tissues present homogeneous without abnormalities.

AGE

11

The cardiac silhouette is mildly elongated, and the region of the atria appears prominent with a hinted valentine shape of the cardiac silhouette in the VD projection. The pulmonary vasculature is within normal limits.

INTERPRETED BY

Sebastian Schaub, DVM
Dr. med. vet. DipECVDI

The trachea is normal in diameter and presents the anticipated course. The luminal outline of the trachea is smooth.

The bronchial tree presents with thin walls and tapers uniformly towards the periphery as expected.

HOSPITAL NAME

Animal Paradise
Hospital

The lung parenchyma presents the expected architecture and opacity; the intrapulmonary vascular branching is seen up to the third order lung vessels.

The diaphragm is well delineated with even surface and the expected mild cranial bulging of the diaphragmatic cupola.

REFERRING VET

Dr. Kristen Hellwarth

Abdomen

The surrounding bony structures are within normal limits.

No abnormalities of the extraabdominal soft tissues are noted. The abdominal wall is smooth and thin.

INVOICE

51305

The serosal detail is maintained throughout the peritoneal and retroperitoneal space.

The liver is appropriate in position, size and presents uniform opacity.

DATE

4-1-22

The splenic head is in the anticipated position and within normal limits for size and opacity. The splenic body and tail are considered normal for position, size, shape and opacity.

Both kidneys are seen and present with normal size, shape, delineation and opacity. The urinary bladder is in its anticipated position. No radiopaque calculi contains a mild amount of fluid.



PATIENT

Teddy Petrosino

The small intestinal loops are of even diameter and non-dilated, a small amount of gas is seen within the small intestinal loops and considered within normal limits.

The colon is seen in the expected position and is empty

SPECIES

Feline

RADIOGRAPHIC DIAGNOSIS

- Mild cardiomegaly without signs of decompensation
- Empty colon
- Mild fluid filled stomach

BREED

DSH

INTERPRETATION OF THE FINDINGS & FURTHER RECOMMENDATIONS

The prominent cardiac silhouette is concerning for underlying cardiomyopathy (e.g. hypertrophic cardiomyopathy). A cardiac echo would be ideal for further workup. If there is significant atrial enlargement ischemic insult to the CNS might be a potential for the described clinical signs.

SEX

MN

The empty gastrointestinal tract is fitting the history of hyporexia. No additional abnormalities of the abdomen are appreciated.

AGE

11

If not done so yet, consider complete blood work.

INTERPRETED BY

Sebastian Schaub, DVM
Dr. med. vet. DipECVDI

HOSPITAL NAME

Animal Paradise
Hospital

REFERRING VET

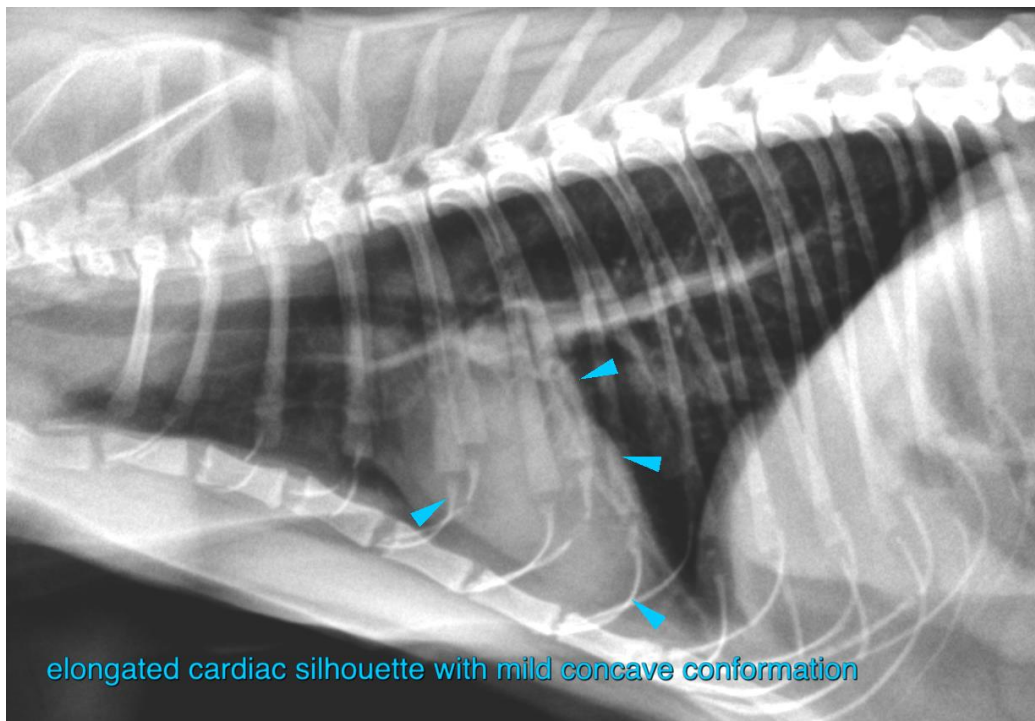
Dr. Kristen Hellwarth

INVOICE

51305

DATE

4-1-22





PATIENT

Teddy Petrosino

The information and recommendations provided are based on the images presented by the referring veterinarian/sonographer. No evaluation can be communicated regarding pathology that was not visible in the image/video clips provided.

SPECIES

Feline

Thank you for this referral. If the clinical or image interpretation does not parallel your findings or if I can be of any further assistance please contact me.

BREED

DSH

Sebastian Schaub, Sebastian Schaub, DVM, Dr. med. vet. DipECVDI
sebast.schaub@gmail.com

SEX

MN

AGE

11

INTERPRETED BY

Sebastian Schaub, DVM
Dr. med. vet. DipECVDI

HOSPITAL NAME

Animal Paradise
Hospital

REFERRING VET

Dr. Kristen Hellwarth

INVOICE

51305

DATE

4-1-22