



## PATIENT

Daisy Alexander

## SPECIES

Canine

## BREED

French Bulldog

## SEX

Female

## AGE

9 Years

## WEIGHT

12.6 kg

## INTERPRETED BY

Sebastian Schaub, DVM  
Dr. med. vet. DipECVDI

## IMAGING PERFORMED BY

Dr. Viktoria Gounari

## HOSPITAL NAME

Animal Trust- Bolton

## REFERRING VET

Dr. Viktoria Gounari

## INVOICE

14138

## DATE

03/09/26

## PRESENTING CLINICAL SIGNS

- History of hemorrhagic gastroenteritis but during the investigations Noted during xray poor contrast within chest and cardiac silhouette not clear; on ultrasound free fluid noted in pleural space. Drained ~360ml seroh+ fluid from R side. On ultrasound post drain ~ 80% fluid removed. Very abnormal area around cranial R thorax heart base region noted. Irregular, tissue very dense, 2 notable areas of "bubble" with hyperechoic contents.

## COMPUTED TOMOGRAPHIC STUDY OF THE THORAX

A high resolution pre- and post-contrast CT study of the thorax is provided for review.

## COMPUTED TOMOGRAPHIC FINDINGS

The bony and surrounding soft tissue structures are within normal limits.

In the right pleural cavity, a moderate amount of gravity dependent, fluid attenuating material is appreciated; the right lung lobes are retracted from the thoracic wall by the fluid attenuating material and present a decreased volume with zones of dystelectasis.

Centered on the base of the heart and the right atrium – extending cranially into the cranial mediastinum – a uniform soft tissue attenuating and irregular strong contrast enhancing, irregular marginated mass is seen; measuring approximately 6.7 x 5.8 x 7.8 cm. The extending into the lumen of the right atrium and encompassing the right pulmonary artery level with the base of the heart. The right pulmonary artery is compressed by the mass effect. The trachea and esophagus are deviated to the right by the mass effect.

In the cranial mediastinum and the periphery of the heart base mass, multiple tortuous vessels are appreciated.

Throughout the lung parenchyma, multiple punctuate mineralization are appreciated.

Small incidental gas pockets are seen within the esophageal lumen, there is no evidence of abnormal dilation.

Originating from the right left adrenal gland, a nodular lesion with focal punctuate mineralization is appreciated.

## COMPUTED TOMOGRAPHIC DIAGNOSIS

- Large heart base mass with invasion of the right atrium and partial obstruction of the right cranial vena cava
- Secondary compression right pulmonary artery
- Right sided pleural effusion
- Left adrenal nodule with dystrophic mineralization
- Multiple regions with dystelectasis of the lung parenchyma
- Pulmonary osteomas

## INTERPRETATION OF THE FINDINGS & FURTHER RECOMMENDATIONS

The CT findings are consistent with primary heart base neoplasia – such as paraganglioma, hemangiosarcoma, rhabdomyosarcoma, other. The heart base mass is extending into the right atrium, and progressive growth can cause complete mechanical obstruction of the cranial vena cava with secondary cranial vena cava syndrome (e.g. edematous swelling along the neck/skull).

The pleural effusion is considered as a paraneoplastic finding.



## PATIENT

Daisy Alexander

## SPECIES

Canine

## BREED

French Bulldog

## SEX

Female

## AGE

9 Years

## WEIGHT

12.6 kg

## INTERPRETED BY

Sebastian Schaub, DVM  
Dr. med. vet. DipECVDI

## IMAGING PERFORMED BY

Dr. Viktoria Gounari

## HOSPITAL NAME

Animal Trust- Bolton

## REFERRING VET

Dr. Viktoria Gounari

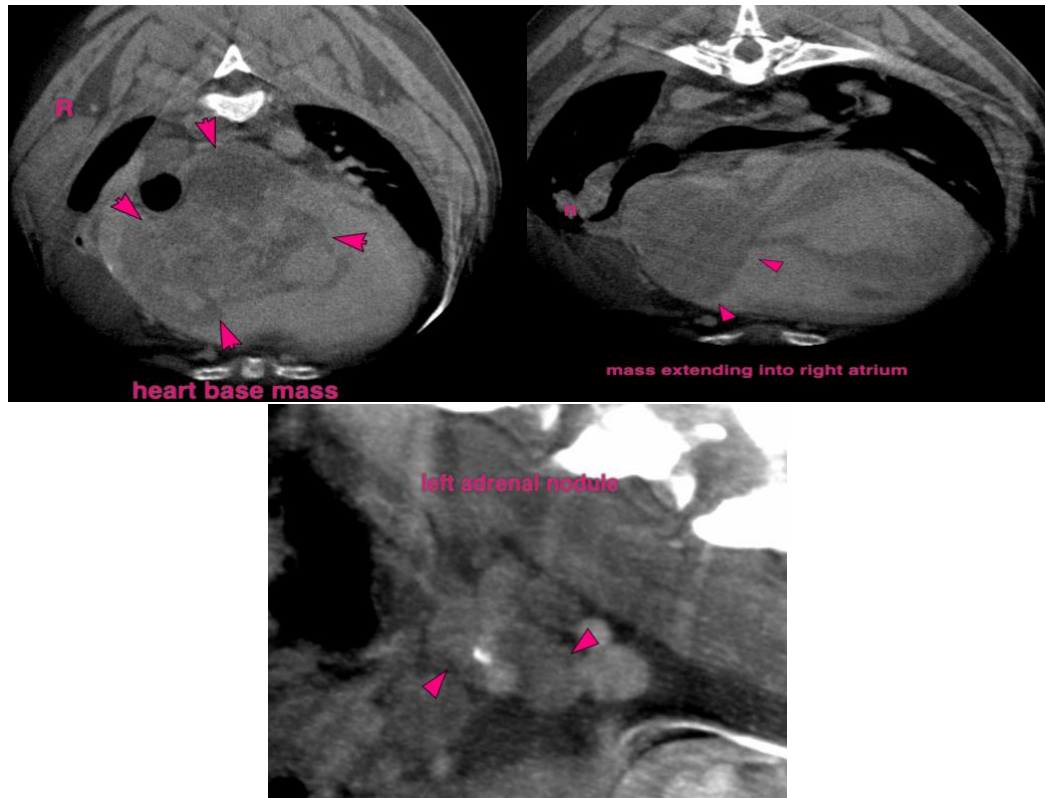
## INVOICE

14138

## DATE

03/09/26

The left adrenal nodule can present (non)functional benign nodular hyperplasia versus neoplastic transformation (e.g. adenoma, adenocarcinoma, pheochromocytoma, metastasis).



The information and recommendations provided are based on the images presented by the referring veterinarian/sonographer. No evaluation can be communicated regarding pathology that was not visible in the image/video clips provided.

Thank you for this referral. If the clinical or image interpretation does not parallel your findings or if I can be of any further assistance please contact me.

Sebastian Schaub, DVM, Dr. med. vet. DipECVDI  
[info@sonopath.com](mailto:info@sonopath.com)