



PATIENT PRESENTING CLINICAL SIGNS

Winyah Barnes Reason for Visit: Check hips History: 2 y/o nm labradoodle presents for a painful right hip of and on since January. O states that it is mainly after laying down after a period of time and then it doesn't hurt the more he walks. P does not like to be touched in that area after he has been laying down for a long time. O is interested in a second opinion.

SPECIES

Canine

BREED

Labradoodle

Abnormal PE/Chem/CBC/UA Results: Hydration: Adequate Mentation: BAR EENT: OU clear. AU clear, no debris. No cough on tracheal palpation. Oral cavity: No dental tartar. Lymph Nodes: Submandibular, prescapular and popliteal lymph nodes normal size, shape and consistency Skin: Healthy hair coat. No ectoparasites seen, skin clean dry and intact. CV/Respiratory: Normal heart rate and rhythm, no murmur, pulses strong and synchronous, normal bronchovesicular sounds. Abd/GI: Soft, non-painful, no fluid wave, no palpable masses or organomegaly. Uro/Perineum: No lesions or abnormalities. Musculoskeletal: BCS = 5/9. Ambulatory x 4, normal gait, normal palpation all 4 limbs. good muscle condition Neurological: Alert and appropriate. No deficits noted.

RADIOGRAPHIC STUDY OF THE PELVIS

SEX

Radiographs of the pelvis in two orthogonal imaging planes are provided for review.

NM

RADIOGRAPHIC FINDINGS

AGE

The VD view of the pelvis is moderately rotated.

2 Years

The osseous and surrounding soft tissue structures of the pelvis are within normal limits. Both coxofemoral joints present smooth osseous margins and congruent joint spaces.

INTERPRETED BY

RADIOGRAPHIC DIAGNOSIS

Sebastian Schaub, DVM
Dr. med. vet. DipECVDI

- Normal pelvis

HOSPITAL NAME

DPC Veterinary
Hospital

INTERPRETATION OF THE FINDINGS & FURTHER RECOMMENDATIONS

The appreciated asymmetry of the coxofemoral joints in the VD projection is considered secondary to the rotation.

Rule out pain originating from the lumbosacral junction/lumbar spine as source for the described clinical signs as well.

REFERRING VET

Dr. Cepero

INVOICE

57170

DATE

3-9-23



PATIENT

Winyah Barnes

SPECIES

Canine

BREED

Labradoodle

SEX

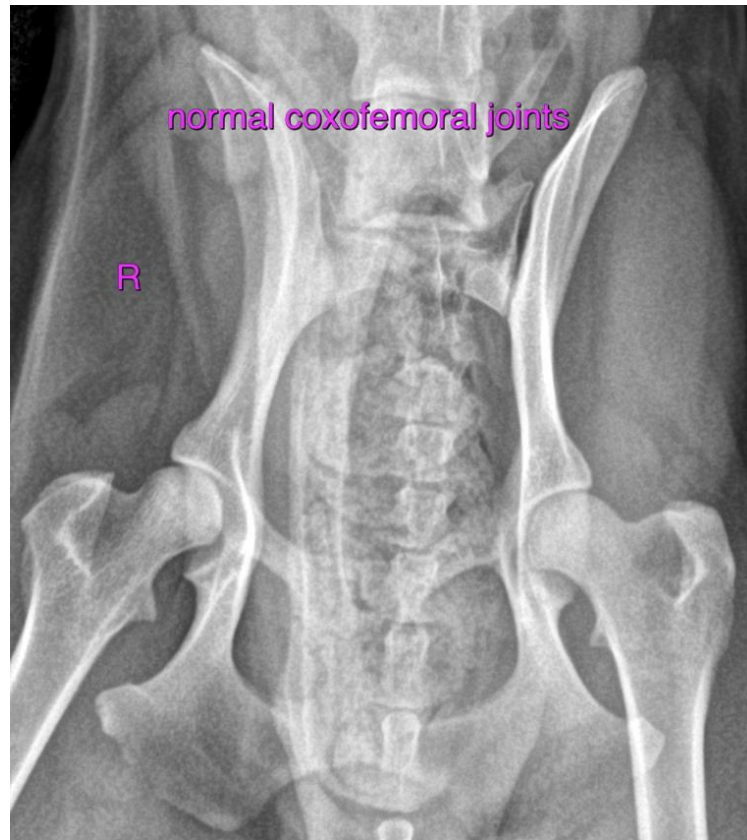
NM

AGE

2 Years

INTERPRETED BY

Sebastian Schaub, DVM
Dr. med. vet. DipECVDI



HOSPITAL NAME

DPC Veterinary
Hospital

The information and recommendations provided are based on the images presented by the referring veterinarian/sonographer. No evaluation can be communicated regarding pathology that was not visible in the image/video clips provided.

REFERRING VET

Dr. Cepero

Thank you for this referral. If the clinical or image interpretation does not parallel your findings or if I can be of any further assistance please contact me.

Sebastian Schaub, Sebastian Schaub, DVM, Dr. med. vet. DipECVDI
sebast.schaub@gmail.com

INVOICE

57170

DATE

3-9-23