

PATIENT PRESENTING CLINICAL SIGNS

Pippi Robbert Inc RR, t-103 F. B/W ok, eating, cough, no murmur,

RADIOGRAPHIC STUDY OF THE THORAX

SPECIES Radiographs of the thorax in three imaging planes are provided for review, dated 3/9/23

K9 RADIOGRAPHIC FINDINGS

The surrounding bony structures are within normal limits.

BREED The extrathoracic soft tissues present homogeneous without abnormalities.

Poo/x The heart is of normal size and shape, there is no evidence of cardiac chamber or vascular enlargement. The pulmonary vasculature is within normal limits.

SEX The cranial mediastinum presents the expected soft tissue opacity. The mediastinal width is less than twice the width of the vertebral column at the same level.

FS The trachea is normal in diameter and presents the anticipated course. The luminal outline of the trachea is smooth.

AGE The bronchial tree presents with thin walls and tapers uniformly towards the periphery as expected.

10 The lung parenchyma presents a generalized moderate unstructured reticular pattern, blurring effacing the pulmonary vasculature; the intrapulmonary vascular branching is seen up to the third order lung vessels.

INTERPRETED BY

The diaphragm is well delineated with even surface and the expected mild cranial bulging of the diaphragmatic cupola.

Sebastian Schaub, DVM
Dr. med. vet. DipECVDI

RADIOGRAPHIC DIAGNOSIS

HOSPITAL NAME

- Generalized moderate unstructured interstitial lung pattern

Bayshore Veterinary
Hospital

INTERPRETATION OF THE FINDINGS & FURTHER RECOMMENDATIONS

REFERRING VET

The unstructured interstitial lung pattern is not specific, and potentials would include fibrosis, pneumonitis (inflammatory versus infectious), systemic disease (e.g. pancreatitis, IMHA, renal disease), neoplasia (e.g. round cell tumor, carcinomatosis). If clinical signs progress/are deteriorating, follow up radiographs can be used to check if consolidation or redistribution of the lung pattern is taking place, potentially allowing to narrow down the differentials list.

Hunt

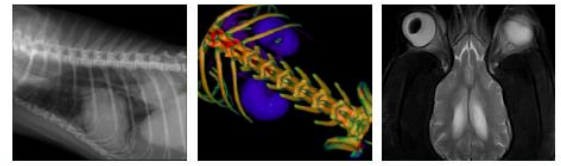
INVOICE

FNA sampling of the lung or bronchoscopy including BAL can be performed as advanced diagnostic tests as well.

57183

DATE

3-9-23



PATIENT

Pippi Robbert

SPECIES

K9

BREED

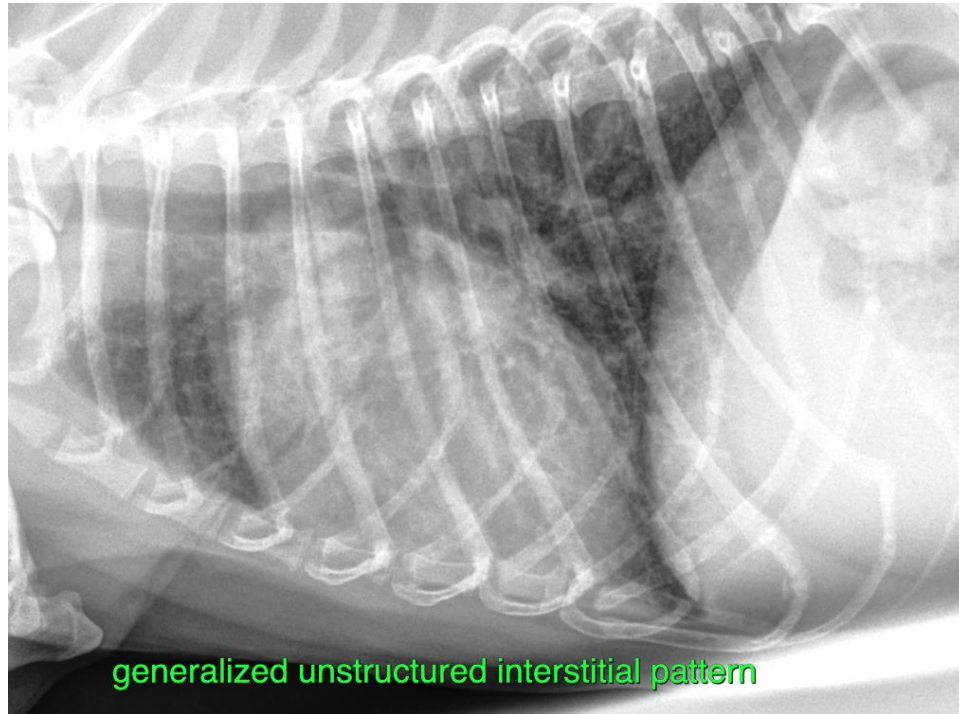
Poo/x

SEX

FS

AGE

10



INTERPRETED BY

Sebastian Schaub, DVM
Dr. med. vet. DipECVDI

HOSPITAL NAME

Bayshore Veterinary
Hospital

REFERRING VET

Hunt

INVOICE

57183

DATE

3-9-23

The information and recommendations provided are based on the images presented by the referring veterinarian/sonographer. No evaluation can be communicated regarding pathology that was not visible in the image/video clips provided.

Thank you for this referral. If the clinical or image interpretation does not parallel your findings or if I can be of any further assistance please contact me.

Sebastian Schaub, Sebastian Schaub, DVM, Dr. med. vet. DipECVDI
sebast.schaub@gmail.com