



PATIENT

Rufus Houston

PRESENTING CLINICAL SIGNS

Abdominal US submitted to sonopath previously, internal medicine consult pending. P has a hx of regenerative anemia with gi blood loss. Temp of 105.5 on presentation, has been on fluids. Has a cough, want to rule out pneumonia.

SPECIES

Ca

RADIOGRAPHIC STUDY OF THE THORAX

Radiographs of the abdomen in three imaging planes are provided for review.

BREED

Pit Bull

RADIOGRAPHIC FINDINGS

The surrounding bony structures are within normal limits.

The extrathoracic soft tissues present homogeneous without abnormalities.

SEX

MN

The heart is of normal size and shape, there is no evidence of cardiac chamber or vascular enlargement. The pulmonary vasculature is within normal limits.

AGE

2

The cranial mediastinum presents the expected soft tissue opacity. The mediastinal width is less than twice the width of the vertebral column at the same level.

The trachea is normal in diameter and presents the anticipated course. The luminal outline of the trachea is smooth.

INTERPRETED BY

Sebastian Schaub, DVM
Dr. med. vet. DipECVDI

Multifocal mild increased visibility of the bronchial walls is appreciated.

The lung parenchyma presents the expected architecture and opacity; the intrapulmonary vascular branching is seen up to the third order lung vessels.

HOSPITAL NAME

Torch Lake
Veterinary Clinic

The diaphragm is well delineated with even surface and the expected mild cranial bulging of the diaphragmatic cupola.

RADIOGRAPHIC DIAGNOSIS

- Mild bronchial lung pattern

REFERRING VET

Adrienne Waffle

INTERPRETATION OF THE FINDINGS & FURTHER RECOMMENDATIONS

The radiographic findings are suggestive for bronchitis. Allergic bronchopneumopathy / eosinophilic and infectious bronchitis – viral, bacterial, parasitic – need to be considered.

INVOICE

50827

There are no signs for pneumonia. If respiratory clinical signs deteriorate, recommend follow up radiographs as radiographic changes can lack behind clinical signs.

DATE

3-9-22



PATIENT

Rufus Houston

SPECIES

Ca

BREED

Pit Bull

SEX

MN

AGE

2

INTERPRETED BY

Sebastian Schaub, DVM
Dr. med. vet. DipECVDI

HOSPITAL NAME

Torch Lake
Veterinary Clinic

REFERRING VET

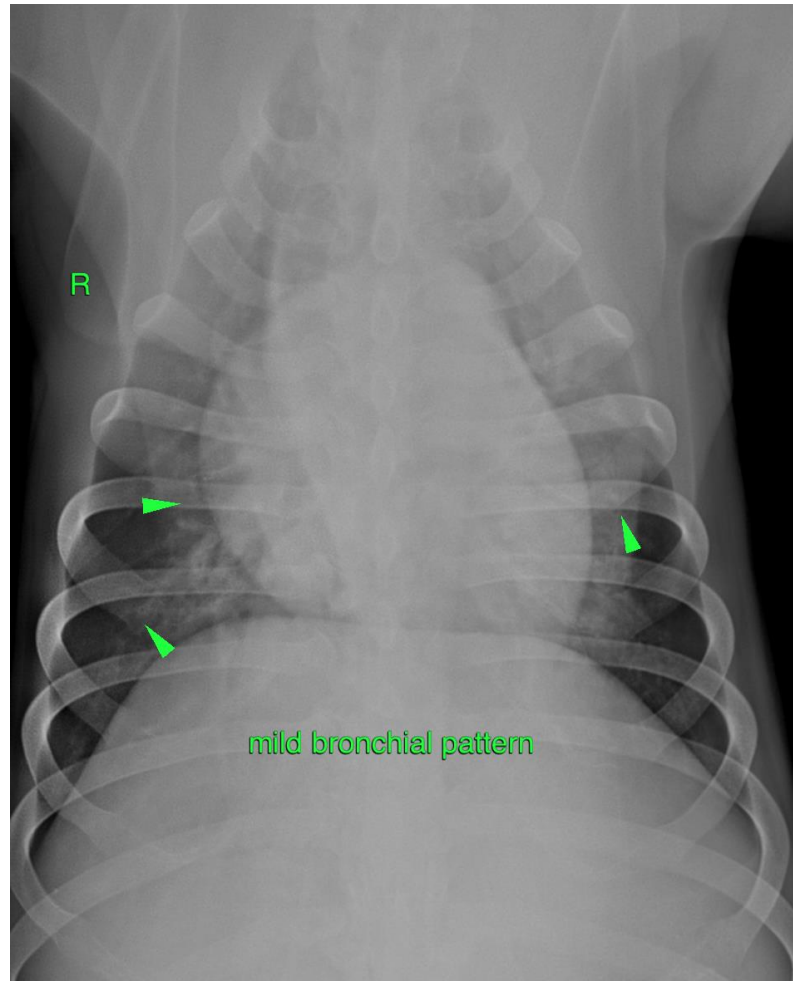
Adrienne Waffle

INVOICE

50827

DATE

3-9-22



The information and recommendations provided are based on the images presented by the referring veterinarian/sonographer. No evaluation can be communicated regarding pathology that was not visible in the image/video clips provided.

Thank you for this referral. If the clinical or image interpretation does not parallel your findings or if I can be of any further assistance please contact me.

Sebastian Schaub, Sebastian Schaub, DVM, Dr. med. vet. DipECVDI
sebast.schaub@gmail.com