

**PATIENT**

Mickey Osband

PRESENTING CLINICAL SIGNS

Mickey came in 3/7/2022 for limping in the hind end. We discovered bite punctures on the R hind leg and tail. The tail is doing good. Mickey is still not putting any weight on his R hind leg and it looks to be swollen. He is on onsiar and he is wearing the cone so he has been laying around more. Abnormal PE/Chem/CBC/UA Results: RIGHT HIND SWOLLEN- EDEMA AND PAINFUL STILL.

SPECIES

Feline

RADIOGRAPHIC STUDY OF THE RIGHT HIND PAW**BREED**

A full set of radiographs of the right hind paw in multiple imaging planes is provided for review.

DSH**RADIOGRAPHIC FINDINGS****SEX**

A generalized, homogeneous, circumferential soft tissue swelling of the right hind paw is appreciated.

M

The osseous structures of the right hind paw are within normal limits.

RADIOGRAPHIC DIAGNOSIS**AGE**

7 Years

- Generalized soft tissue swelling right hind paw
- No evidence of osseous abnormalities

INTERPRETED BY

Sebastian Schaub, DVM
Dr. med. vet. DipECVDI

INTERPRETATION OF THE FINDINGS & FURTHER RECOMMENDATIONS

Given the history of bite wounds, the generalized swelling of the right hind paw is indicating local inflammation. Ultrasound might be used to check for pockets of fluid, warranting surgical drainage.

HOSPITAL NAME

EI

REFERRING VET

Leon Anderson, DVM

INVOICE

50852

DATE

3-9-22



PATIENT

Mickey Osband

SPECIES

Feline

BREED

DSH

SEX

M

AGE

7 Years

INTERPRETED BY

Sebastian Schaub, DVM
Dr. med. vet. DipECVDI

HOSPITAL NAME

EI

REFERRING VET

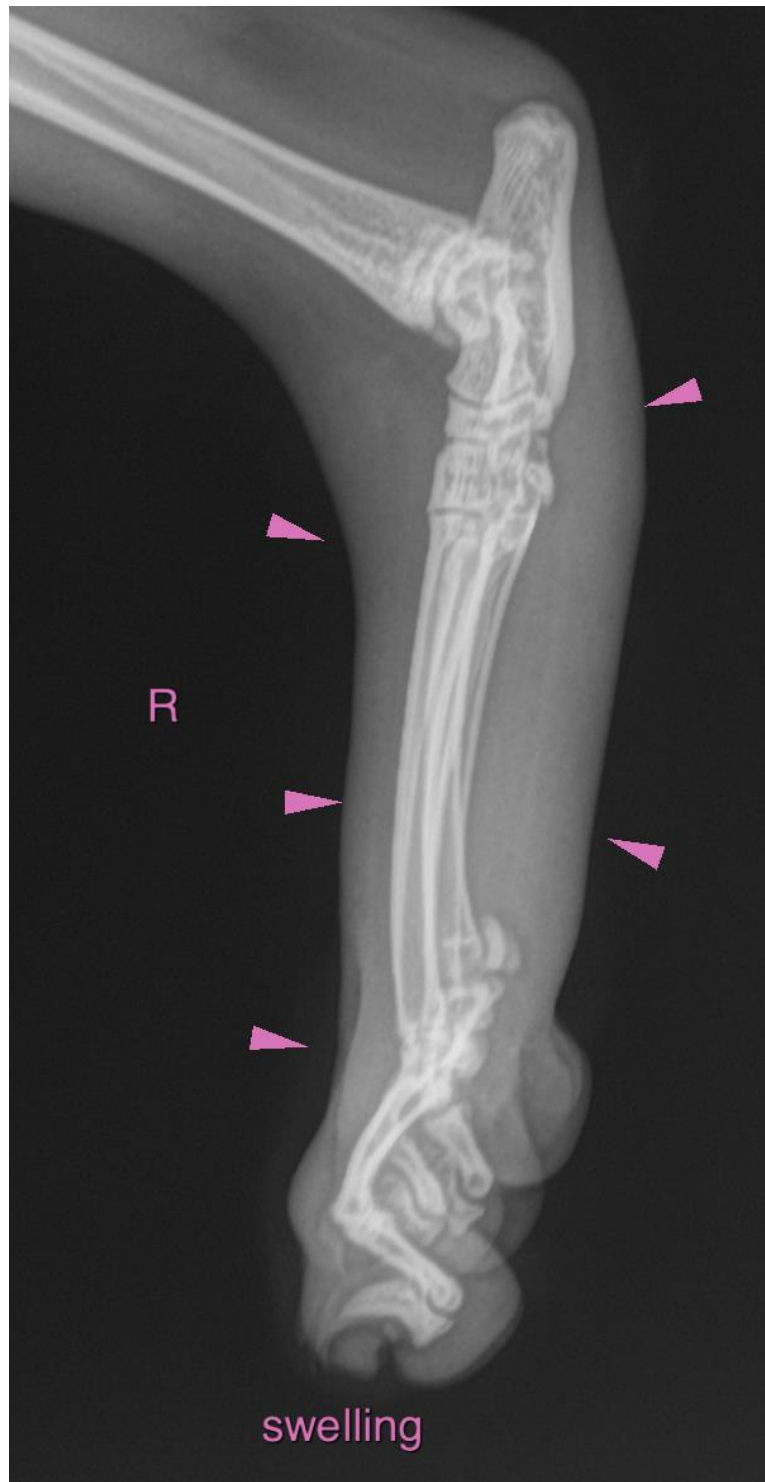
Leon Anderson, DVM

INVOICE

50852

DATE

3-9-22





PATIENT

Mickey Osband

The information and recommendations provided are based on the images presented by the referring veterinarian/sonographer. No evaluation can be communicated regarding pathology that was not visible in the image/video clips provided.

SPECIES

Feline

Thank you for this referral. If the clinical or image interpretation does not parallel your findings or if I can be of any further assistance please contact me.

BREED

DSH

Sebastian Schaub, Sebastian Schaub, DVM, Dr. med. vet. DipECVDI
sebast.schaub@gmail.com

SEX

M

AGE

7 Years

INTERPRETED BY

Sebastian Schaub, DVM
Dr. med. vet. DipECVDI

HOSPITAL NAME

EI

REFERRING VET

Leon Anderson, DVM

INVOICE

50852

DATE

3-9-22