



PATIENT PRESENTING CLINICAL SIGNS

Calypso Diaz Rechecking: back right leg/ x ray History: 5 m Pitbull presented for a recheck of back right leg. Splint fell off yesterday so O bathed pet and cleaned with chlorhexidine cleaner.

SPECIES Abnormal PE/Chem/CBC/UA Results: Exam Notes: BARH. Integ--wounds right hindlimb have almost healed--one focal superficial scab, no discharge. Erythema and hair regrowth evident. M/S-- ambulatory x 4, moderate weight-bearing to toe-touching lameness right pelvic limb. Did not perform full orthopedic exam. Visible cranial displacement of tibial plateau.
Canine

RADIOGRAPHIC STUDY OF THE PELVIS

BREED Radiographs of the pelvis and right stifle joint are provided for review.

Pitbull **RADIOGRAPHIC FINDINGS**

SEX The osseous and surrounding soft tissue structures of the pelvis are within normal limits. Both coxofemoral joints present smooth osseous margins and congruent joint spaces.

Female The volume of the right thigh musculature is mild to moderately decreased in comparison to the contralateral limb.

AGE The patella of the right stifle joint is in a relative more proximal position in comparison to the left stifle joint.

5 Months The tibial tuberosity of the right stifle joint is stationary in a horizontally oriented position. Advanced mineralization is seen along the apophysis of the tibial tuberosity in comparison to the preceding radiographic study.

INTERPRETED BY

RADIOGRAPHIC DIAGNOSIS

Sebastian Schaub, DVM
Dr. med. vet. DipECVDI

- History of right sided avulsion fracture of the right tibial tuberosity, stationary horizontal orientation of the tibial tuberosity and progressive mineralization of the apophysis
- Secondary mild right sided patella alta
- Disuse atrophy musculature right hind limb
- Normal pelvis

HOSPITAL NAME

DPC Veterinary Hospital

INTERPRETATION OF THE FINDINGS & FURTHER RECOMMENDATIONS

REFERRING VET The radiographic study presents malunion of the tibial tuberosity of the right tibia, following avulsion fracture. The fracture is in the reparation phase.

Dr. Ward

INVOICE

57146

DATE

3-8-23



PATIENT

Calypso Diaz

SPECIES

Canine

BREED

Pitbull

SEX

Female

AGE

5 Months

INTERPRETED BY

Sebastian Schaub, DVM
Dr. med. vet. DipECVDI

HOSPITAL NAME

DPC Veterinary
Hospital

REFERRING VET

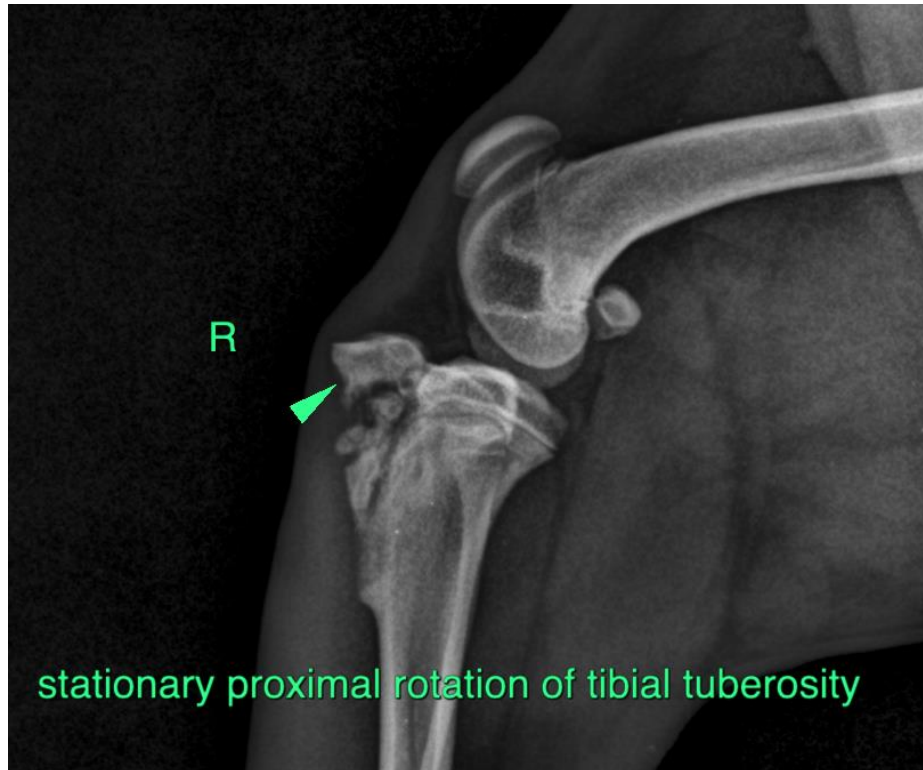
Dr. Ward

INVOICE

57146

DATE

3-8-23



The information and recommendations provided are based on the images presented by the referring veterinarian/sonographer. No evaluation can be communicated regarding pathology that was not visible in the image/video clips provided.

Thank you for this referral. If the clinical or image interpretation does not parallel your findings or if I can be of any further assistance please contact me.

Sebastian Schaub, Sebastian Schaub, DVM, Dr. med. vet. DipECVDI
sebast.schaub@gmail.com