



PATIENT PRESENTING CLINICAL SIGNS

Ace Chalmers Reason for Visit: Limping History: 2 y/o nm american bulldog presents for limping on his left hind leg for about a month. O says it comes and goes, and sometimes sees his hip being painful, P will occasionally lick the limping leg. Also has occasional/environmental skin allergies, is currently red on his chest and has a dark rash on his left shoulder area (O put on an antifungal cream).

SPECIES

Canine

BREED

American Bulldog

SEX

NM

Abnormal PE/Chem/CBC/UA Results: Hydration: Adequate Mentation: BAR EENT: OU clear. AU clear, no debris. No cough on tracheal palpation. Oral cavity: mild/moderate dental tartar. Lymph Nodes: Submandibular, prescapular and popliteal lymph nodes normal size, shape and consistency Skin: Healthy hair coat. No ectoparasites seen, moist erythema and crusting in both elbows, both axillas, ventral abdomen and chest have pinpoint raised red lesions- CV/Respiratory: Normal heart rate and rhythm, no murmur, pulses strong and synchronous, normal bronchovesicular sounds. Abd/GI: Soft, non-painful, no fluid wave, no palpable masses or organomegaly. Uro/Perineum: No lesions or abnormalities. Musculoskeletal: BCS = 8/9. obese Ambulatory x 4, toe touching left hind, orthopedic exam performed undersedation, moderate drawer and mild thrust left stifle, right side normal Neurological: Alert and appropriate. No deficits noted.

RADIOGRAPHIC STUDY OF THE LEFT STIFLE JOINT

Radiographs of the left stifle joint are provided for review.

AGE

2 Years, 10 Months

RADIOGRAPHIC FINDINGS

The periarticular bones of the left stifle joint present moderate osteophyte new bone formation. A moderate intracapsular soft tissue swelling of the left stifle joint is seen, distorting the infrapatellar fat pad cranially and the fascial plane caudally. Significant supination of the left stifle joint in the craniocaudal view is present.

INTERPRETED BY

Sebastian Schaub, DVM
Dr. med. vet. DipECVDI

RADIOGRAPHIC DIAGNOSIS

- Degenerative osteoarthritis left stifle joint
- Articular swelling left stifle joint

HOSPITAL NAME

DPC Veterinary Hospital

INTERPRETATION OF THE FINDINGS & FURTHER RECOMMENDATIONS

The radiographic study is consistent with left sided chronic degenerative osteoarthritis with concomitant joint effusion of the stifle joint. The most-likely underlying cause is (partial) rupture of the cranial cruciate ligament with or without meniscal disease.

REFERRING VET

Dr. Cepero

A positive drawer sign or tibial compression test under general anesthesia can be used to confirm the diagnosis.

INVOICE

57144

DATE

3-8-23



PATIENT

Ace Chalmers

SPECIES

Canine

BREED

American Bulldog

SEX

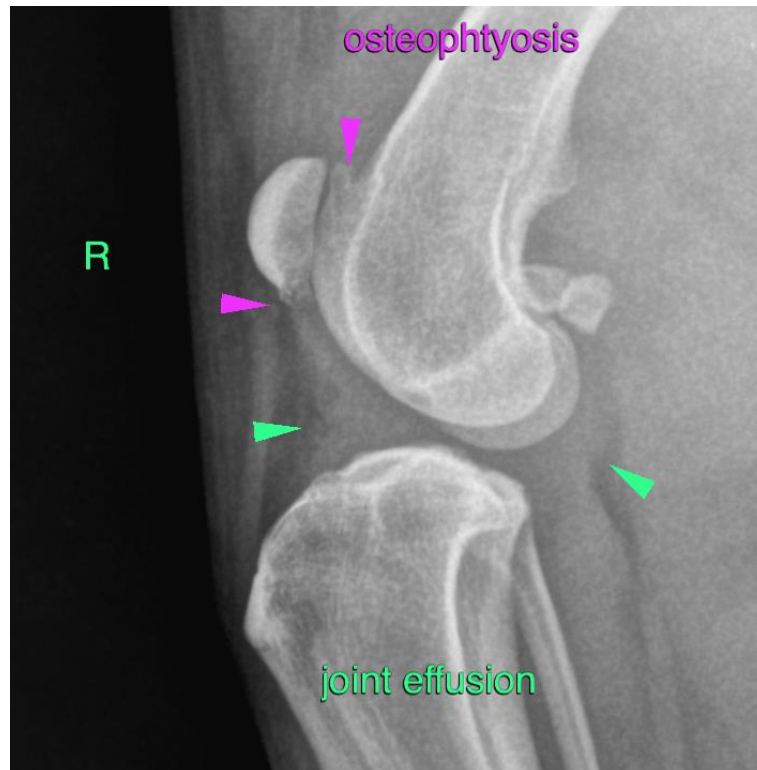
NM

AGE

2 Years, 10 Months

INTERPRETED BY

Sebastian Schaub, DVM
Dr. med. vet. DipECVDI



HOSPITAL NAME

DPC Veterinary
Hospital

REFERRING VET

Dr. Cepero

INVOICE

57144

DATE

3-8-23

The information and recommendations provided are based on the images presented by the referring veterinarian/sonographer. No evaluation can be communicated regarding pathology that was not visible in the image/video clips provided.

Thank you for this referral. If the clinical or image interpretation does not parallel your findings or if I can be of any further assistance please contact me.

Sebastian Schaub, Sebastian Schaub, DVM, Dr. med. vet. DipECVDI
sebast.schaub@gmail.com