



PATIENT

Snarky McQueen

PRESENTING CLINICAL SIGNS

Recent history of urinary accidents, leaking urine, blood in urine for 1-2 days. No previous urinary issues in past. Placed on Buprenorphine oral, c/d diet, and given Convenia inj. 3/7/22. Abnormal PE/Chem/CBC/UA Results: NSF on CBC,CHEM

SPECIES

Fel

RADIOGRAPHIC STUDY OF THE ABDOMEN

A laterolaterale projection of the abdomen is provided for review.

BREED

DSH

RADIOGRAPHIC FINDINGS

The surrounding bony structures are within normal limits.

SEX

NM

No abnormalities of the extraabdominal soft tissues are noted. The abdominal wall is smooth and thin.

The liver is appropriate in position, size and presents uniform opacity.

Both kidneys are seen and present with normal size, shape, delineation and opacity.

AGE

8.5 Years

The urinary bladder is mildly distended and contains a mild to moderate amount of unformed mineral opaque material. The peritoneal fat surrounding the urinary bladder presents moderate fat-stranding.

INTERPRETED BY

Sebastian Schaub, DVM
Dr. med. vet. DipECVDI

The stomach is in its anticipated position and presents normal content.

The small intestinal loops are of even diameter and non-dilated, a small amount of gas is seen within the small intestinal loops and considered within normal limits.

HOSPITAL NAME

Long Valley Animal
Hospital

The colon is seen in the expected position and presents with appropriate content.

RADIOGRAPHIC DIAGNOSIS

- Urinary calculi/bladder sand
- Focal peritonitis surrounding the urinary bladder

REFERRING VET

Dr. Welch

INTERPRETATION OF THE FINDINGS & FURTHER RECOMMENDATIONS

The empty urinary bladder with the bladder sand/cystolithiasis and localized peritonitis is highly suggestive for cystitis. If not done so yet, complete urinalysis is indicated for further definition. There are no signs for mechanical obstruction. Given the mineralized material in the center of the urinary bladder, I suspect significant generalized thickening of the urinary bladder wall.

INVOICE

50814

DATE

3-8-22



PATIENT

Snarky McQueen

SPECIES

Fel

BREED

DSH

SEX

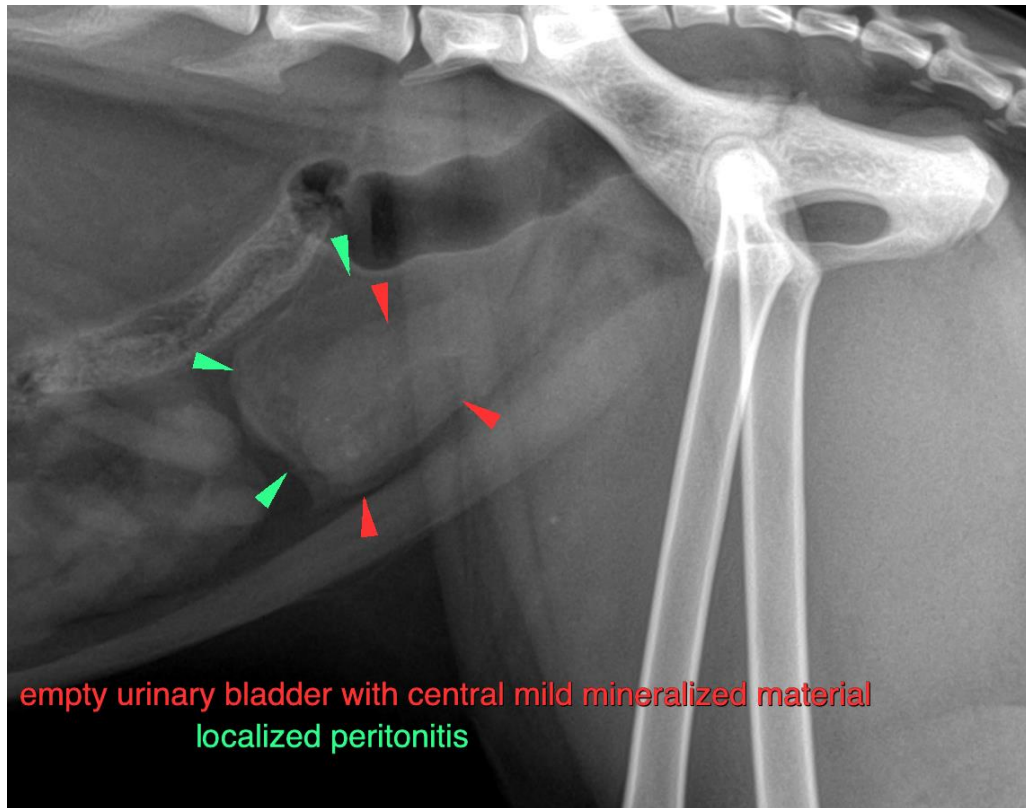
NM

AGE

8.5 Years

INTERPRETED BY

Sebastian Schaub, DVM
Dr. med. vet. DipECVDI



empty urinary bladder with central mild mineralized material
localized peritonitis

HOSPITAL NAME

Long Valley Animal
Hospital

REFERRING VET

Dr. Welch

INVOICE

50814

DATE

3-8-22

The information and recommendations provided are based on the images presented by the referring veterinarian/sonographer. No evaluation can be communicated regarding pathology that was not visible in the image/video clips provided.

Thank you for this referral. If the clinical or image interpretation does not parallel your findings or if I can be of any further assistance please contact me.

Sebastian Schaub, Sebastian Schaub, DVM, Dr. med. vet. DipECVDI
sebast.schaub@gmail.com