



**PATIENT PRESENTING CLINICAL SIGNS**

Matisse Gatti Left perianal mass effect: R/O Anal sac ACA verse other CT of chest through Abdomen with contrast for staging

**SPECIES COMPUTED TOMOGRAPHY OF THE THORAX AND ABDOMEN**

Canine A high resolution post-contrast CT study of the thorax and abdomen is provided for review.

**BREED COMPUTED TOMOGRAPHIC FINDINGS**

Labrador Thorax

The thorax presents with moderate motion artefacts.

**SEX** The bony and surrounding soft tissue structures are within normal limits.

**MN** The sternal, cranial mediastinal and tracheobronchial lymph nodes are small elongated with a normal short-to-long-axis-ratio is < 0.5, the attenuation and contrast enhancement pattern is uniform and considered within normal limits.

**AGE** The cardiovascular structures including the pulmonary vasculature are within normal limits.

11 Years The bronchial tree presents with regular branching and tapers uniformly towards the periphery as expected, the bronchial walls are thin and smooth. The bronchus-to-artery ratio is within normal limits.

**INTERPRETED BY**

Sebastian Schaub, DVM  
Dr. med. vet. DipECVDI

The lung parenchyma presents the expected architecture and attenuation behavior.

Small incidental gas pockets are seen within the esophageal lumen, there is no evidence of abnormal dilation.

**HOSPITAL NAME**

Animal Surgical Center Abdomen

Moderate motion artefacts are seen throughout the cranial abdomen.

**REFERRING VET**

Dr. R. Lombardi The serosal fat presents normal attenuation behavior. There is no evidence of peritoneal effusion or peritonitis.

Both kidneys present within normal limits for size, shape and organ architecture. After contrast administration a bilaterally symmetric and uniform nephro- and pyelogram is noted.

**INVOICE**

50820 The adrenal glands are within normal limits for size, shape and organ architecture.

**DATE**

3-8-22 Originating from the left anal sac, an irregular margins, heterogeneous contrast enhancing soft tissue mass, measuring 5.2 x 4.1 x 6.4 cm in size is visible, distorting the rectum & anus at the same level.



**PATIENT**

Matisse Gatti

Generalized marked enlargement of the sacral lymph nodes is seen, presenting a heterogeneous contrast enhancement pattern and protruding ventrally into the pelvic canal. The rectum is deviated to the right by the mass effect.

The bony and surrounding soft tissue structures reveal no abnormalities.

**SPECIES**

Canine

**COMPUTED TOMOGRAPHIC DIAGNOSIS**

- Large soft tissue mass left anal sac
- Marked lymphadenopathy sacral lymph nodes
- No evidence of pulmonary metastatic disease

**BREED**

Labrador

**INTERPRETATION OF THE FINDINGS & FURTHER RECOMMENDATIONS**

The findings are supporting the diagnosis of left sided adenocarcinoma, originating from the anal sac. The mass lesions ventral to the sacrum indicate metastatic spread to the regional lymph nodes. FNA sampling of the masses can be performed to confirm the diagnosis and potential palliative treatment options can be discussed with oncologist – complete excision of the affected lymph nodes appears not feasible.

**SEX**

MN

**AGE**

11 Years

**INTERPRETED BY**

Sebastian Schaub, DVM  
Dr. med. vet. DipECVDI

**HOSPITAL NAME**

Animal Surgical  
Center

**REFERRING VET**

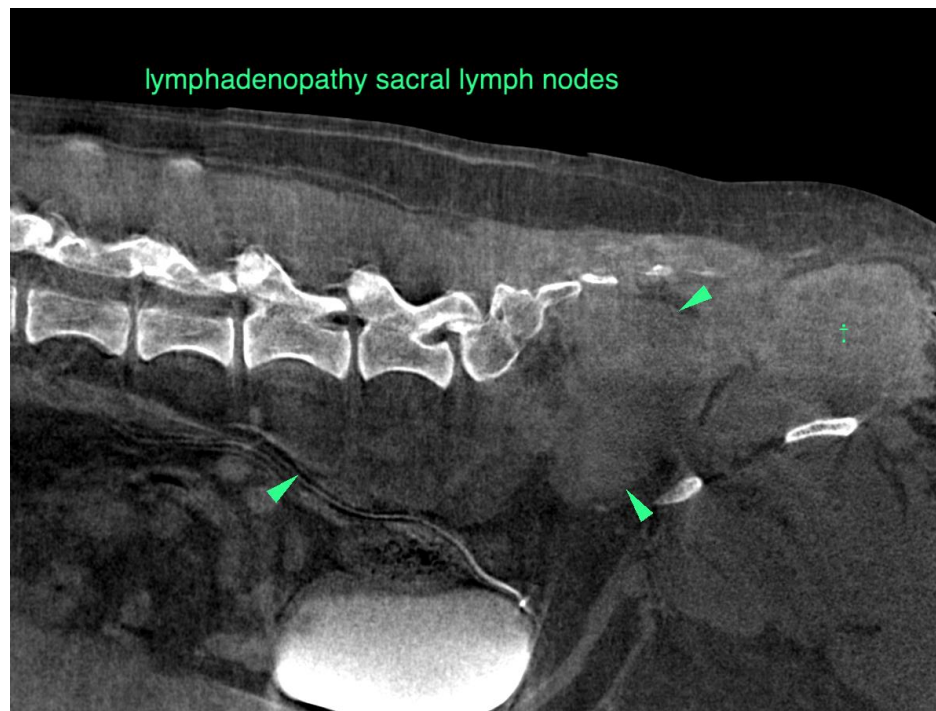
Dr. R. Lombardi

**INVOICE**

50820

**DATE**

3-8-22





**PATIENT**

Matisse Gatti

**SPECIES**

Canine

**BREED**

Labrador

**SEX**

MN

**AGE**

11 Years

**INTERPRETED BY**

Sebastian Schaub, DVM  
Dr. med. vet. DipECVDI

**HOSPITAL NAME**

Animal Surgical  
Center

**REFERRING VET**

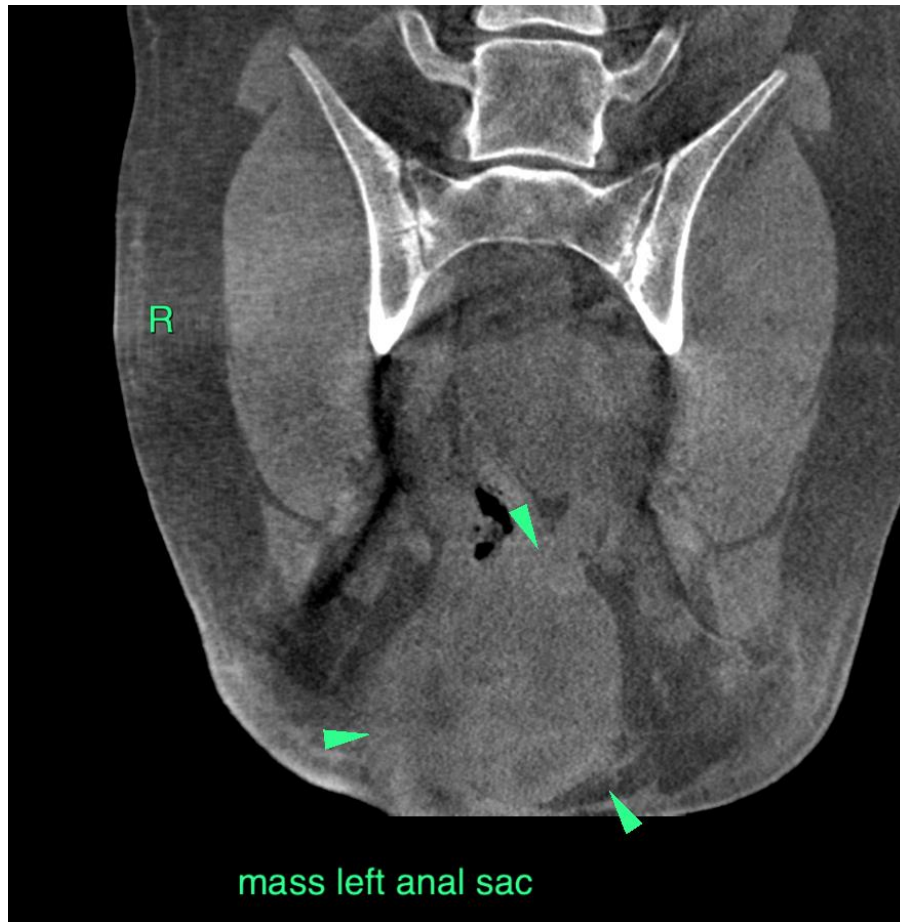
Dr. R. Lombardi

**INVOICE**

50820

**DATE**

3-8-22



The information and recommendations provided are based on the images presented by the referring veterinarian/sonographer. No evaluation can be communicated regarding pathology that was not visible in the image/video clips provided.

Thank you for this referral. If the clinical or image interpretation does not parallel your findings or if I can be of any further assistance please contact me.

**Sebastian Schaub**, Sebastian Schaub, DVM, Dr. med. vet. DipECVDI  
sebast.schaub@gmail.com