



PATIENT PRESENTING CLINICAL SIGNS

Jive Blumenthal Patient had small abrasion on lip about about a week ago. Swelling developed on the left side of face yesterday. History of IBS.

SPECIES COMPUTED TOMOGRAPHY OF THE SKULL

Canine A high resolution pre- and post-contrast CT study of the skull is provided for review.

COMPUTED TOMOGRAPHIC FINDINGS

BREED
Labrador A supernumerary triadan 203 is seen. Triadan 105, 106 and 406 are absent. Mild to moderate abrasion of the crowns of triadan 104, 204, 304 and 404 is noted. Triadan 305&405 are retained within the alveolar bone

SEX The left lips are diffuse swollen.

FS In the left submandibular region, a moderate subcutaneous swelling with a heterogeneous contrast enhancement pattern is seen.

AGE A small gas inclusion is seen level with the lateral of the left mandibular lymph nodes.

The nasal cavity presents the expected aerated spaces between thin & even conchae and turbinates with smooth mucosal lining.

INTERPRETED BY

Sebastian Schaub, DVM
Dr. med. vet. DipECVDI

Both temporomandibular joints present congruent joint spaces with even subchondral bone surfaces and are considered within normal limits.

Both tympanic bullae are aerated, the mucosal lining is not seen, the bony wall is smooth and thin. The external ear canals are within normal limits.

HOSPITAL NAME

Wilvet Salem

The brain presents no deviation from normal anatomy and symmetry. The brain parenchyma is homogeneous and within normal limits for attenuation and distribution of contrast enhancement. The ventricular system is non-dilated and symmetric.

REFERRING VET

Brittany Gardner
DVM

The left medial retropharyngeal lymph node is prominent.

COMPUTED TOMOGRAPHIC DIAGNOSIS

- Subcutaneous steatitis left submandibular region
- Inflammatory edema left aspect of the viscerocranium
- Mild lymphadenopathy left medial retropharyngeal lymph node
- Unerupted triadan 305&405
- Absent triadan 105, 106 and 406

INVOICE

50776

INTERPRETATION OF THE FINDINGS & FURTHER RECOMMENDATIONS

DATE

3-8-22

The focal swelling in the left submandibular region is concerning for early stage of abscess formation with secondary inflammatory edema along the left aspect of the viscerocranium. At this point no distinct abscess is appreciated. Rule out potential insect bite as source for the swelling as well. Consider tapping the swelling in the left submandibular region. Ultrasound can



PATIENT

Jive Blumenthal

be used to check for fluid accumulation and will allow FNA sampling of the prominent left medial retropharyngeal lymph node.

SPECIES

Canine

BREED

Labrador

SEX

FS

AGE

13

INTERPRETED BY

Sebastian Schaub, DVM
Dr. med. vet. DipECVDI

HOSPITAL NAME

Wilvet Salem

REFERRING VET

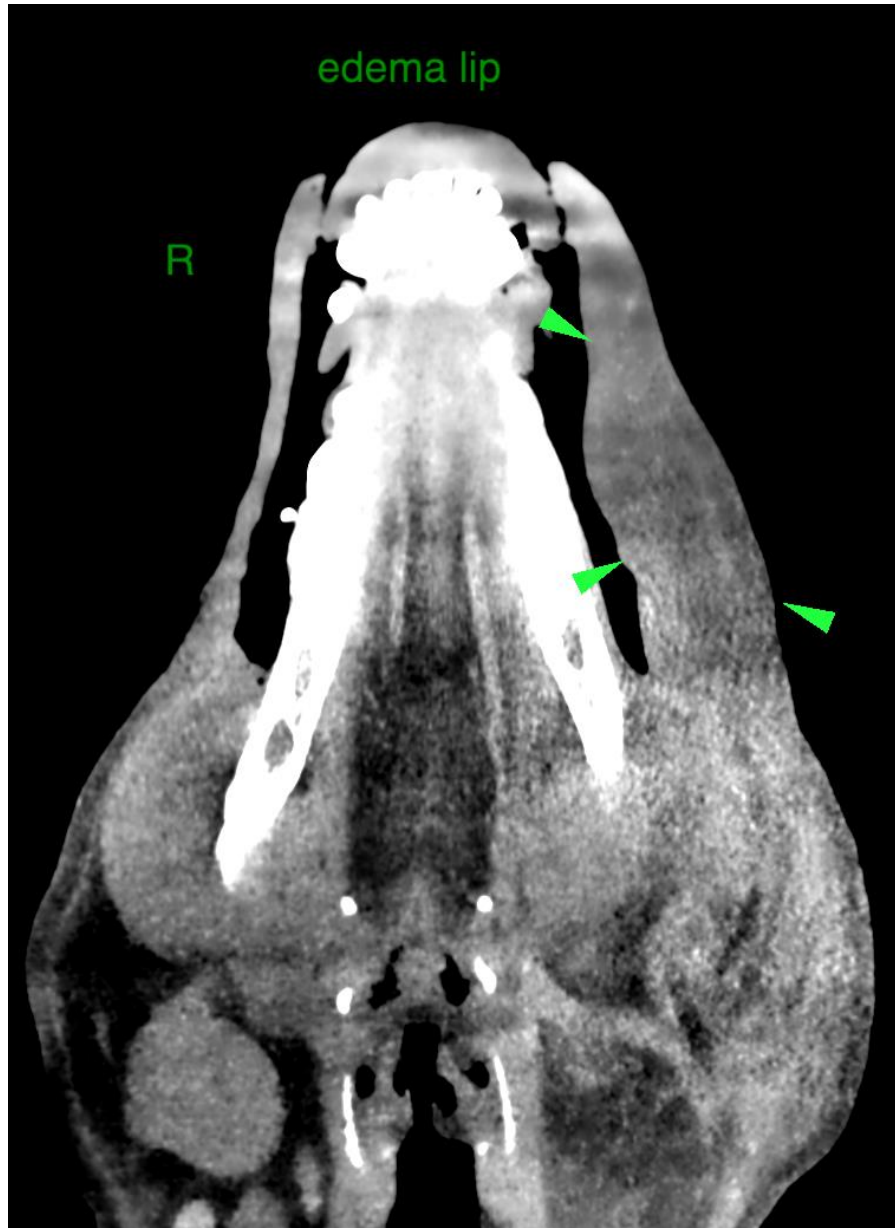Brittany Gardner
DVM

INVOICE

50776

DATE

3-8-22





PATIENT

Jive Blumenthal

SPECIES

Canine

BREED

Labrador

SEX

FS

AGE

13

INTERPRETED BY

Sebastian Schaub, DVM
Dr. med. vet. DipECVDI

HOSPITAL NAME

Wilvet Salem

REFERRING VET

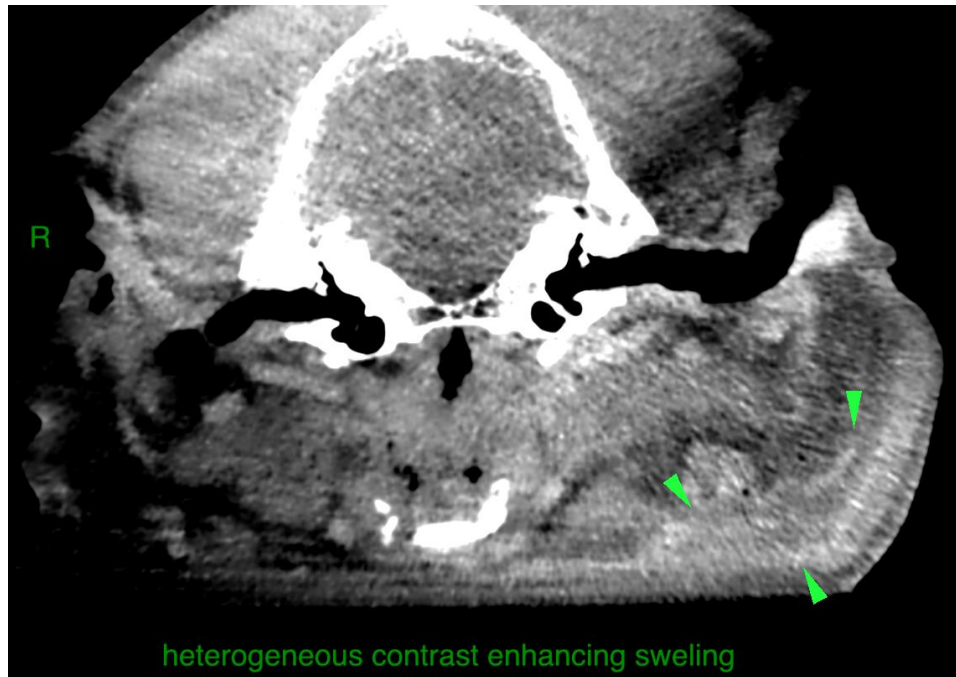
Brittany Gardner
DVM

INVOICE

50776

DATE

3-8-22



The information and recommendations provided are based on the images presented by the referring veterinarian/sonographer. No evaluation can be communicated regarding pathology that was not visible in the image/video clips provided.

Thank you for this referral. If the clinical or image interpretation does not parallel your findings or if I can be of any further assistance please contact me.

Sebastian Schaub, Sebastian Schaub, DVM, Dr. med. vet. DipECVDI
sebast.schaub@gmail.com