



PATIENT PRESENTING CLINICAL SIGNS

PATIENT
 Coco Barchuk
 Coco is a ten year old, FS, Cockapoo with a distant history of cervical IVDD. Recently, since September 2021, Coco has been limping on right front leg. On exam, she has mild crepitus of the right carpus and is resentful with pressure on her elbow area. She has a grade 3 lameness right front leg with a head bob at a walk/trot. Coco resents right neck flexion and will subtly turn her body to avoid extreme right neck flexion. There is also right carpal valgus that is more pronounced today than it has been. Coco's lameness has not been responsive to Dasuquin advanced, carprofen or gabapentin. Right shoulder, right carpus and cervical spine films are submitted for evaluation of cause of right front leg lameness.

SPECIES
 Canine

BREED RADIOGRAPHIC STUDY OF THE CERVICAL SPINE & FRONT LIMBS

BREED
 Cockapoo
 Radiographs of the cervical spine and front limbs in two imaging planes are provided for review.

SEX RADIOGRAPHIC FINDINGS

SEX
 FS
 The radiographic study of the cervical spine is moderately rotated. The intervertebral disc space C3/C4 is moderately narrowed in the VD projection.

AGE
 Both shoulder joints present smooth osseous margins, unremarkable.

10.5 Years
 The periarticular bones of the right elbow joint present moderate osteophyte new bone formation. The contour of the medial coronoid process of the right elbow joint is ill-defined and a moderate sclerosis is seen at the base of the medial coronoid process. The left elbow joint presents with smooth osseous margins.

INTERPRETED BY

Sebastian Schaub, DVM
 Dr. med. vet. DipECVDI

Both carpal joints present moderate osteophyte new bone formation, L>R. The carpal joints present a mild intracapsular circumferential soft tissue swelling.

HOSPITAL NAME RADIOGRAPHIC DIAGNOSIS

Lambs Gap Animal Hospital

- Degenerative osteoarthritis carpal joints bilaterally with mild to moderate articular swelling, L>R
- Degenerative osteoarthritis right elbow joint due to pathology of the medial coronoid process
- Suspect discopathy C3/C4
- Normal shoulder joints bilaterally

REFERRING VET

Dr. Jennifer Todd

INTERPRETATION OF THE FINDINGS & FURTHER RECOMMENDATIONS

INVOICE

50800

Both the degenerative osteoarthritis of the right elbow joint as well as the degenerative joint disease of the carpal joint are potential sources for right front limb lameness. The changes of the right elbow joint are secondary to disease of the medial coronoid process (e.g. FCP). The articular swelling of the stifle joint can be secondary to degenerative joint disease, to rule out accompanying inflammatory origin a synovial tap might be used as advanced diagnostic test.

DATE

3-8-22

For further evaluation of the right elbow joint, a CT study can be considered.



PATIENT

Coco Barchuk

SPECIES

Canine

BREED

Cockapoo

SEX

FS

AGE

10.5 Years

INTERPRETED BY

Sebastian Schaub, DVM
Dr. med. vet. DipECVDI

HOSPITAL NAME

Lambs Gap Animal
Hospital

REFERRING VET

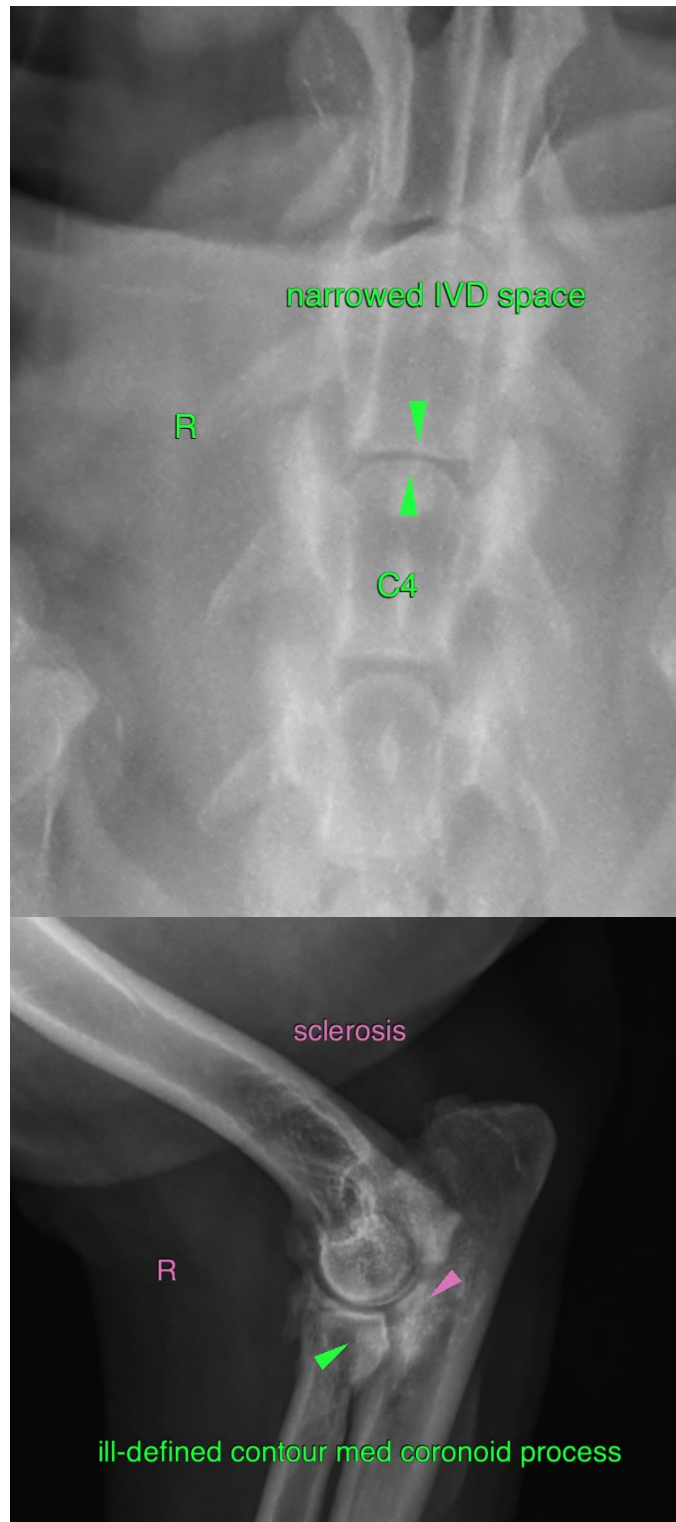
Dr. Jennifer Todd

INVOICE

50800

DATE

3-8-22





PATIENT

Coco Barchuk

SPECIES

Canine

BREED

Cockapoo

SEX

FS

AGE

10.5 Years

INTERPRETED BY

Sebastian Schaub, DVM
Dr. med. vet. DipECVDI

HOSPITAL NAME

Lambs Gap Animal
Hospital

REFERRING VET

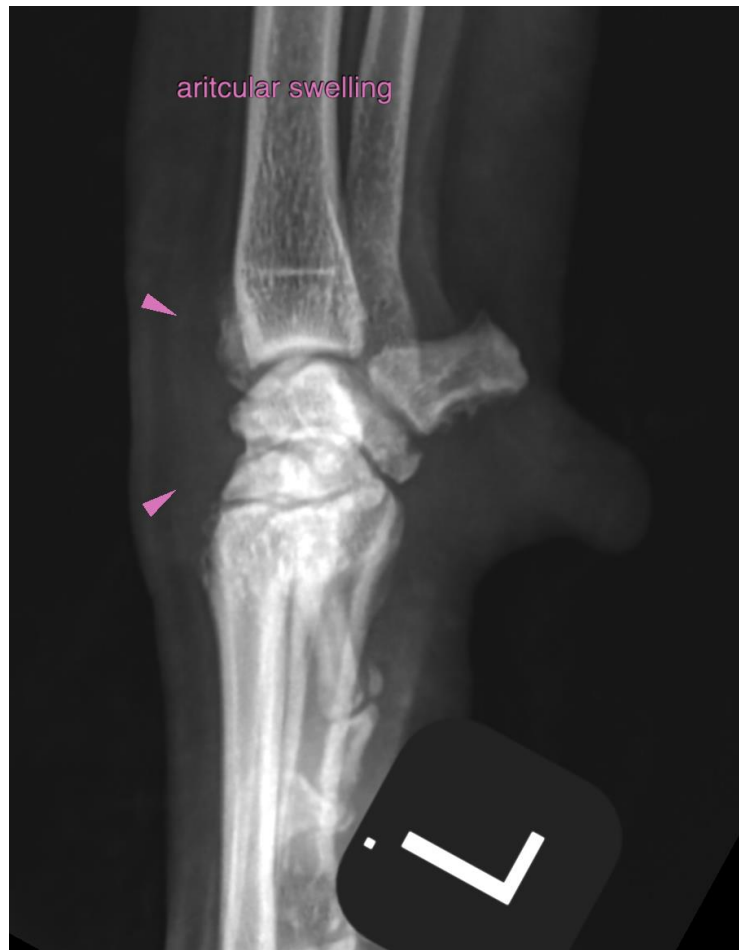Dr. Jennifer Todd

INVOICE

50800

DATE

3-8-22



The information and recommendations provided are based on the images presented by the referring veterinarian/sonographer. No evaluation can be communicated regarding pathology that was not visible in the image/video clips provided.

Thank you for this referral. If the clinical or image interpretation does not parallel your findings or if I can be of any further assistance please contact me.

Sebastian Schaub, Sebastian Schaub, DVM, Dr. med. vet. DipECVDI
sebast.schaub@gmail.com