



PATIENT PRESENTING CLINICAL SIGNS

Arkham Morello Pet presented for CT Scan evaluation of skull due to approx two month history of acute onset increased aggression and increased appetite.

SPECIES COMPUTED TOMOGRAPHY OF THE SKULL

Canine A high resolution pre- and post-contrast CT study of the skull is provided for review.

COMPUTED TOMOGRAPHIC FINDINGS

BREED

The pictured parts of the dentition are complete and unremarkable in all jaw quadrants.

German Shepard

The nasal cavity presents the expected aerated spaces between thin & even conchae and turbinates with smooth mucosal lining.

SEX

Both temporomandibular joints present congruent joint spaces with even subchondral bone surfaces and are considered within normal limits.

MN

Both tympanic bullae are aerated, the mucosal lining is not seen, the bony wall is smooth and thin. The external ear canals are within normal limits.

AGE

2 Years

The brain presents no deviation from normal anatomy and symmetry. The brain parenchyma is homogeneous and within normal limits for attenuation and distribution of contrast enhancement. The ventricular system is non-dilated and symmetric.

INTERPRETED BY

The right mandibular lymph nodes are prominent.

Sebastian Schaub, DVM
Dr. med. vet. DipECVDI

COMPUTED TOMOGRAPHIC DIAGNOSIS

HOSPITAL NAME

- Mild lymphadenopathy right mandibular lymph nodes
- Structural normal brain

Mobile Pet Imaging
CFL

INTERPRETATION OF THE FINDINGS & FURTHER RECOMMENDATIONS

The prominent mandibular lymph nodes are most consistent with reactive hyperplasia – FNA sampling can be used to confirm the diagnosis.

REFERRING VET

Borecky

If not yet done so, the workup should be complemented by examination of CSF and complete bloodwork to screen for brain disease that is not necessarily associated with structural changes of the brain parenchyma and rule out hepatoencephalopathy and other systemic illness. In case of the strong clinical suspicion of structural intraparenchymal changes, an MRI may be considered.

INVOICE

50812

DATE

3-8-22



PATIENT

Arkham Morello

SPECIES

Canine

BREED

German Shepard

SEX

MN

AGE

2 Years

INTERPRETED BY

Sebastian Schaub, DVM
Dr. med. vet. DipECVDI

HOSPITAL NAME

Mobile Pet Imaging
CFL

REFERRING VET

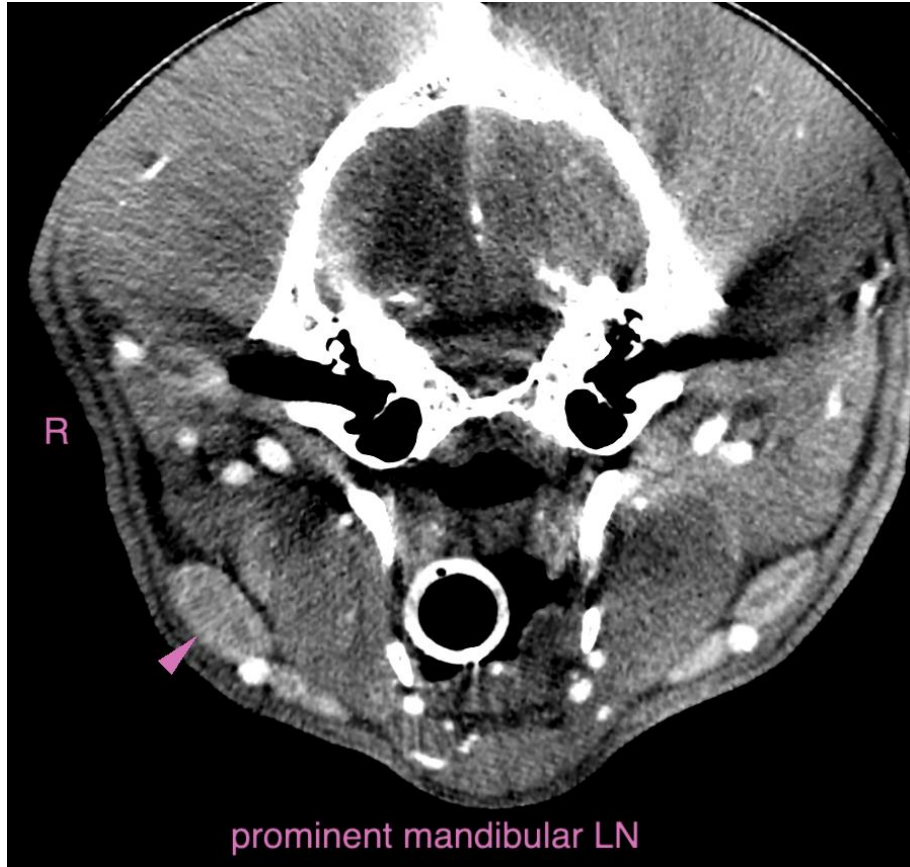
Borecky

INVOICE

50812

DATE

3-8-22



prominent mandibular LN

The information and recommendations provided are based on the images presented by the referring veterinarian/sonographer. No evaluation can be communicated regarding pathology that was not visible in the image/video clips provided.

Thank you for this referral. If the clinical or image interpretation does not parallel your findings or if I can be of any further assistance please contact me.

Sebastian Schaub, Sebastian Schaub, DVM, Dr. med. vet. DipECVDI
sebast.schaub@gmail.com