



**PATIENT PRESENTING CLINICAL SIGNS**

Tarzan Pletta P presents for labored breathing. O states P has a Hx of cough and has been on hydrocodone for the last 2 years. O states tonight P was having a hard time breathing and was neck extending. O also mentioned P had a seizure about a year ago, unknown as to what caused it.

**SPECIES** Abnormal PE/Chem/CBC/UA Results: Dyspnea without oxygen support - eupneic in oxygen  
 Canine Oxygen-dependent Radiographs show evidence of bronchopneumonia r/o infectious vs inflammatory vs neoplastic vs auto-immune vs other

**COMPUTED TOMOGRAPHY OF THE THORAX**

**BREED** A high resolution pre- and post-contrast CT study of the thorax is provided for review.

German Shepherd **COMPUTED TOMOGRAPHIC FINDINGS**

Regarding the anatomy, electronic side markers are flipped, R is actually indicating the left side of the patient and vice versa.

**SEX** Multifocal spondylosis formation is seen along the thoracic spine.

MN The sternal, cranial mediastinal and tracheobronchial lymph nodes are small elongated with a normal short-to-long-axis-ratio is < 0.5, the attenuation and contrast enhancement pattern is uniform and considered within normal limits.

**AGE** The cardiovascular structures including the pulmonary vasculature are within normal limits.

9 The bronchial tree presents with regular branching and tapers uniformly towards the periphery as expected, the bronchial walls are thin and smooth. The bronchus-to-artery ratio is within normal limits.

**INTERPRETED BY**

Sebastian Schaub, DVM  
 Dr. med. vet. DipECVDI

The volume of the right cranial and right middle lung lobe is decreased and the lung parenchyma is consolidated in the ventral regions of the respective lung lobes with air-bronchograms. In the ventral dependent aspect of the caudal part of the left cranial lung lobe, a zone with consolidation of the lung parenchyma is seen. The lung parenchyma presents the expected architecture and attenuation behavior. Randomly distributed punctuate mineralization of the parenchyma of multiple lung lobes is seen.

**HOSPITAL NAME**

Scottsdale Veterinary  
 Clinic

The bronchial walls predominantly of the left lung lobes are mildly thickened.

**REFERRING VET**

Samantha Gans

Small incidental gas pockets are seen within the esophageal lumen, there is no evidence of abnormal dilation.

**COMPUTED TOMOGRAPHIC DIAGNOSIS**

**INVOICE**

57101

- Cranioventrally distributed alveolar lung pattern, R>L
- Mild bronchial pattern left, L>R
- Pulmonary osteomas
- Spondylosis deformans

**DATE**

3-7-23

**INTERPRETATION OF THE FINDINGS & FURTHER RECOMMENDATIONS**

The appreciated lung pattern is supporting the diagnosis of pneumonia, bacterial origin is considered most likely.

The pulmonary changes appear only mild referring to severity of the described clinical signs.



**PATIENT**

Tarzan Pletta

Complementing workup by a cardiac echo can be used to screen for signs of pulmonary hypertension due to possible thrombus formation in the capillary bed and secondary oxygenation disorder – no thrombus material is appreciated in the large pulmonary vessels.

**SPECIES**

Canine

**BREED**

German Shepherd

**SEX**

MN

**AGE**

9

**INTERPRETED BY**

Sebastian Schaub, DVM  
Dr. med. vet. DipECVDI

**HOSPITAL NAME**

Scottsdale Veterinary  
Clinic

**REFERRING VET**

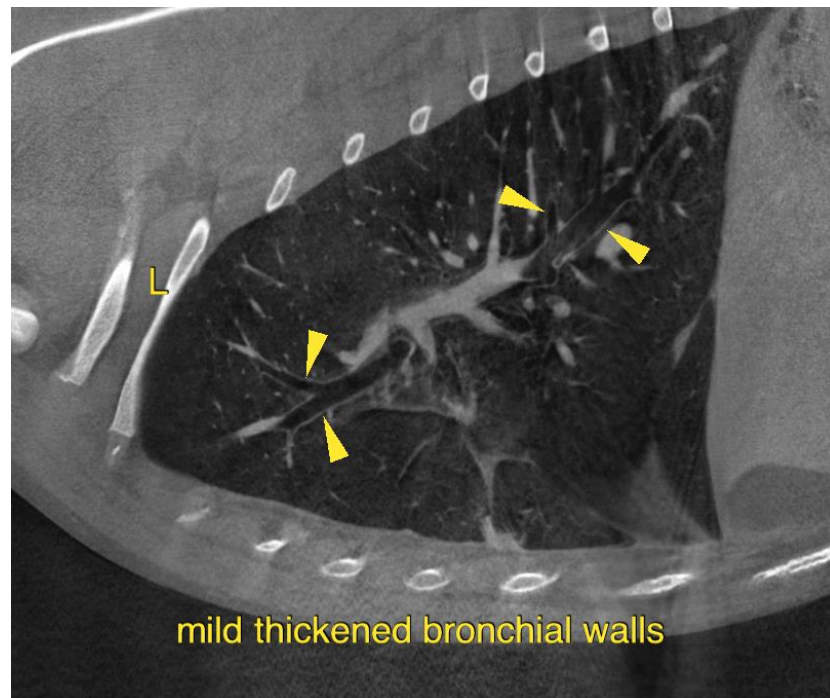
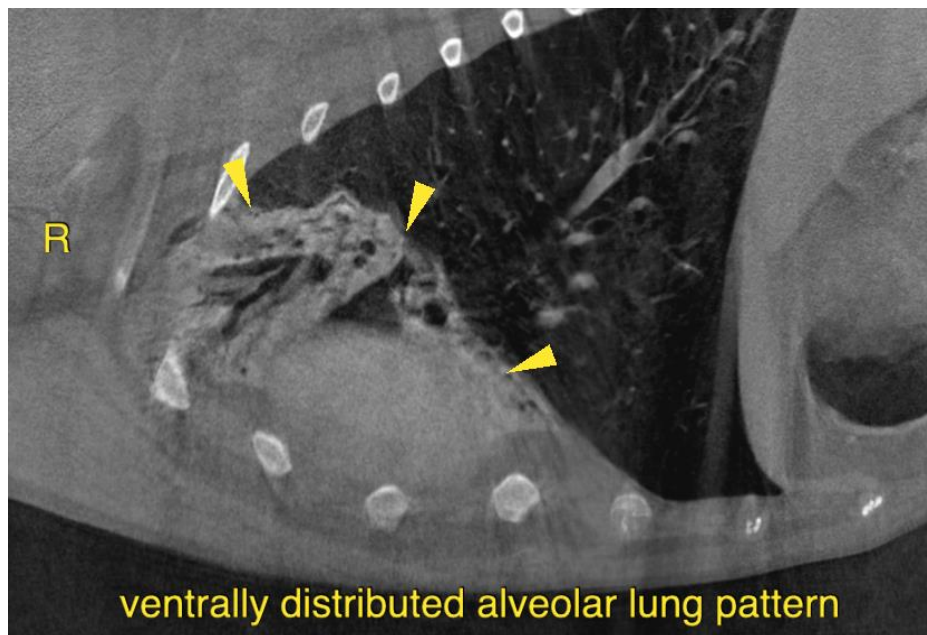
Samantha Gans

**INVOICE**

57101

**DATE**

3-7-23





**PATIENT**

Tarzan Pletta

**SPECIES**

Canine

**BREED**

German Shepherd

**SEX**

MN

**AGE**

9

**INTERPRETED BY**

Sebastian Schaub, DVM  
Dr. med. vet. DipECVDI

**HOSPITAL NAME**

Scottsdale Veterinary  
Clinic

**REFERRING VET**

Samantha Gans

**INVOICE**

57101

**DATE**

3-7-23

The information and recommendations provided are based on the images presented by the referring veterinarian/sonographer. No evaluation can be communicated regarding pathology that was not visible in the image/video clips provided.

Thank you for this referral. If the clinical or image interpretation does not parallel your findings or if I can be of any further assistance please contact me.

**Sebastian Schaub**, Sebastian Schaub, DVM, Dr. med. vet. DipECVDI  
sebast.schaub@gmail.com