

**PATIENT**

Ollie Moe

SPECIES

Feline

BREED

Domestic Shorthair

SEX

Neutered Male

AGE

12 Years, 9 Months

INTERPRETED BYSebastian Schaub, DVM
Dr. med. vet. DipECVDI**HOSPITAL NAME**Ahwatukee Commons
Veterinary Hospital**REFERRING VET**

Linda Elliott, D.V.M.

INVOICE

50769

DATE

3-7-22

PRESENTING CLINICAL SIGNS

Pt presents with unresolved sneezing going on for at least November, 2021. Pt has history of asthma and has received Convenia injections and Baytril oral suspension previously. Nasal discharge has resolved and sneezing has improved but is still there. Owner states that Pt is still having breathing issues - per Owner - sounds like Pt is gurgling/wheezing. Feline upper respiratory panel sent, pending results. Doctor did not see any lesions on skull radiographs but would like consult.

RADIOGRAPHIC STUDY OF THE SKULL

Radiographs of the skull in multiple imaging planes are provided for review.

RADIOGRAPHIC FINDINGS

One tympanic bulla – suspect the left tympanic bulla – presents a moderately thickened wall. In the lateral projection, a convex shaped soft tissue opacity is occupying the caudal aspect of the caudal nasopharynx.

Multiple teeth are absent.

The remainder of the osseous and soft tissue structures of the skull are within normal limits.

RADIOGRAPHIC DIAGNOSIS

- Soft tissue mass nasopharynx
- Suspect unilateral otitis media (left?)
- Multiple absent teeth

INTERPRETATION OF THE FINDINGS & FURTHER RECOMMENDATIONS

The soft tissue opacification of the nasopharynx is highly suggestive for nasopharyngeal mass; in combination with the suspected otitis media inflammatory polyp is a potential as well as neoplastic disease (e.g. lymphosarcoma). Recommend retrograde endoscopy of the nasopharynx for further definition. A CT study of the skull can be used as advanced imaging modality as well.



PATIENT

Ollie Moe

SPECIES

Feline

BREED

Domestic Shorthair

SEX

Neutered Male

AGE

12 Years, 9 Months

INTERPRETED BY

Sebastian Schaub, DVM
Dr. med. vet. DipECVDI

HOSPITAL NAME

Ahwatukee Commons
Veterinary Hospital

REFERRING VET

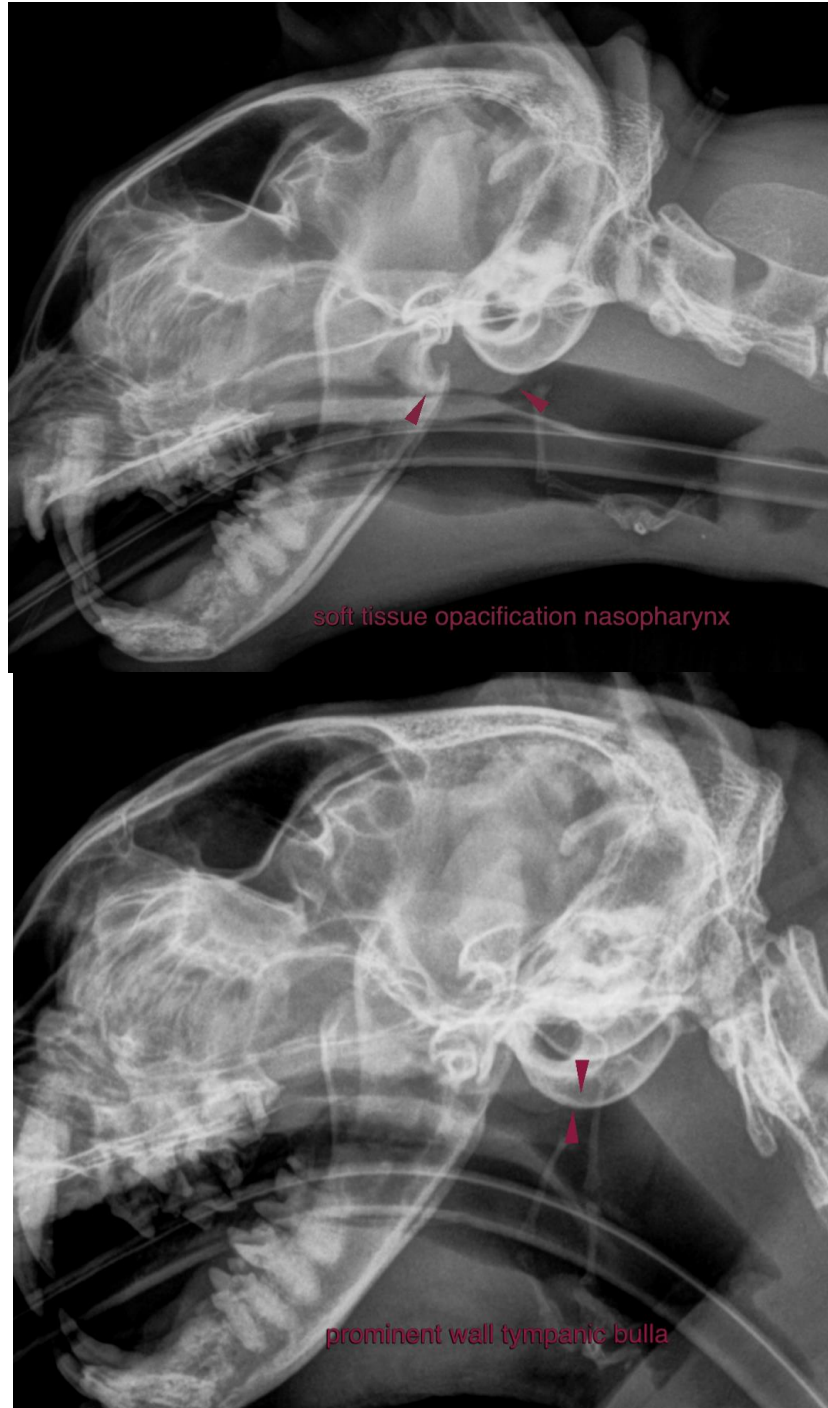
Linda Elliott, D.V.M.

INVOICE

50769

DATE

3-7-22





PATIENT

Ollie Moe

The information and recommendations provided are based on the images presented by the referring veterinarian/sonographer. No evaluation can be communicated regarding pathology that was not visible in the image/video clips provided.

SPECIES

Feline

Thank you for this referral. If the clinical or image interpretation does not parallel your findings or if I can be of any further assistance please contact me.

BREED

Domestic Shorthair

Sebastian Schaub, Sebastian Schaub, DVM, Dr. med. vet. DipECVDI
sebast.schaub@gmail.com

SEX

Neutered Male

AGE

12 Years, 9 Months

INTERPRETED BY

Sebastian Schaub, DVM
Dr. med. vet. DipECVDI

HOSPITAL NAME

Ahwatukee Commons
Veterinary Hospital

REFERRING VET

Linda Elliott, D.V.M.

INVOICE

50769

DATE

3-7-22