



PATIENT PRESENTING CLINICAL SIGNS

Clover Boise Pt is here for a possible partial collapsed lobe in the lungs. Pt was referred by Schrag Animal Clinic where rads were taken and O was told about the partial collapse. O said that pt may have ingested a piece of rubber and she is afraid that it may be stuck. O said that she did not actually see the pt ingest the rubber, but she knows that mom brought some into the puppy pen and pt symptoms started shortly after. Other 6 puppies are fine. O also mentioned about the possibility that the wheezing sound may be a result of anxiety, since it seems to only happen when pt is alone or in a busy environment. Performed a scope and did not see a foreign body.

SPECIES Canine

BREED Labrador Retriever

Abnormal PE/Chem/CBC/UA Results: Elevated Values:Reticulocytes-164.0 K/uL, Lymphocytes-7.1 K/uL, Monocytes-2.14 K/uL, MPV-13.7 fL, Plateletcrit-0.62% Decreased Values:RBC-4.09 M/uL, Hematocrit-24.7%, Hemoglobin-8.3 g/dL, MVC-60.4 g/dL, MCH- 20.3 pg, Reticulocyte Hemoglobin- 20.5 pg, Total Protein-4.5 g/dL

COMPUTED TOMOGRAPHY OF THE SKULL & THORAX

SEX A high resolution pre- and post-contrast CT study of the skull and thorax are provided for review.

Male

COMPUTED TOMOGRAPHIC FINDINGS

Generalized age related immaturity of the skeletal structures is seen.

AGE

6 Weeks

Skull

INTERPRETED BY

Sebastian Schaub, DVM
Dr. med. vet. DipECVDI

The pictured parts of the dentition including the tooth buds are unremarkable in all jaw quadrants.

The nasal cavity presents the expected aerated spaces between thin & even conchae and turbinates with smooth mucosal lining.

HOSPITAL NAME

Neel Veterinary
Hospital

Both temporomandibular joints present congruent joint spaces with even subchondral bone surfaces and are considered within normal limits.

Both tympanic bullae are aerated, the mucosal lining is not seen, the bony wall is smooth and thin. The external ear canals are within normal limits.

REFERRING VET

Dr. Deepan Kishore

The brain presents no deviation from normal anatomy and symmetry. The brain parenchyma is homogeneous and within normal limits for attenuation and distribution of contrast enhancement. The ventricular system is non-dilated and symmetric.

INVOICE

50792

The submandibular and medial retropharyngeal lymph nodes are small and elongated with a normal short-to-long-axis-ratio is < 0.5, the attenuation and contrast enhancement pattern is uniform.

Thorax

DATE

3-7-22

The bony and surrounding soft tissue structures are within normal limits.

The cranial mediastinum is moderately widened by the thymus.

The cardiovascular structures including the pulmonary vasculature are within normal limits.



PATIENT

Clover Boise

The bronchial tree presents with regular branching and tapers uniformly towards the periphery as expected, the bronchial walls are thin and smooth. The bronchus-to-artery ratio is within normal limits.

The lung parenchyma presents the expected architecture and attenuation behavior.

SPECIES

Canine

Small incidental gas pockets are seen within the esophageal lumen, there is no evidence of abnormal dilation.

BREED

Labrador Retriever

COMPUTED TOMOGRAPHIC DIAGNOSIS

- Normal skull
- Normal thorax

INTERPRETATION OF THE FINDINGS & FURTHER RECOMMENDATIONS

SEX

Male

The CT study of the skull presents without abnormalities, there is no evidence of foreign material.

AGE

6 Weeks

INTERPRETED BY

Sebastian Schaub, DVM
Dr. med. vet. DipECVDI

HOSPITAL NAME

Neel Veterinary
Hospital

REFERRING VET

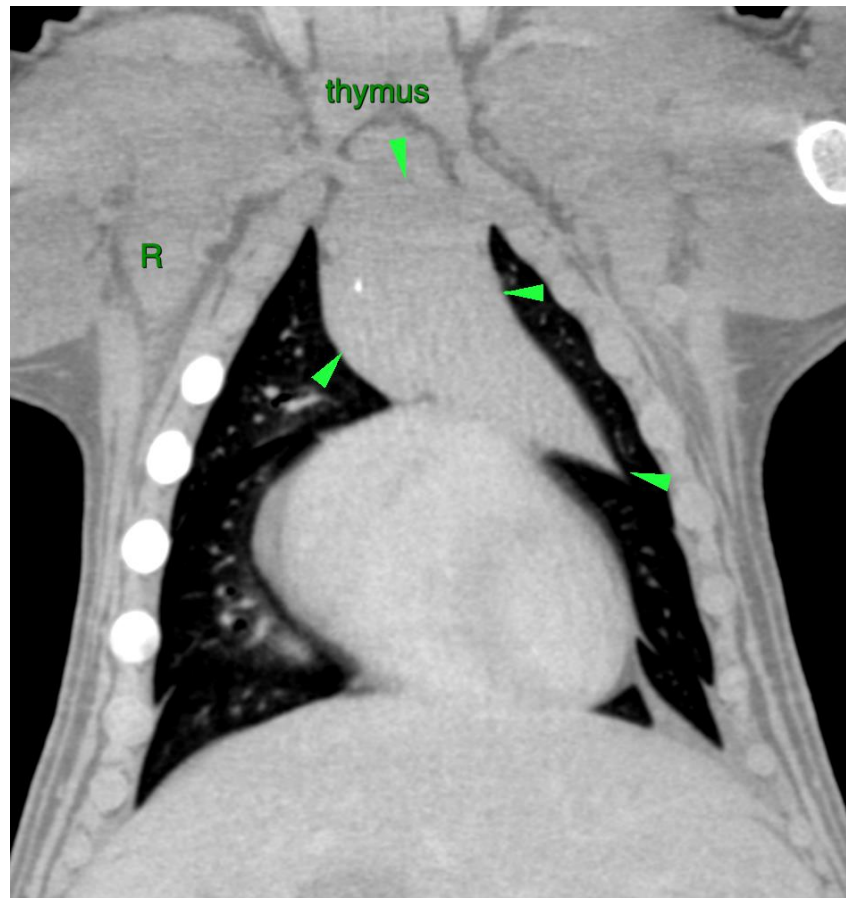
Dr. Deepan Kishore

INVOICE

50792

DATE

3-7-22





PATIENT

Clover Boise

The information and recommendations provided are based on the images presented by the referring veterinarian/sonographer. No evaluation can be communicated regarding pathology that was not visible in the image/video clips provided.

Thank you for this referral. If the clinical or image interpretation does not parallel your findings or if I can be of any further assistance please contact me.

SPECIES

Canine

Sebastian Schaub, Sebastian Schaub, DVM, Dr. med. vet. DipECVDI
sebast.schaub@gmail.com

BREED

Labrador Retriever

SEX

Male

AGE

6 Weeks

INTERPRETED BY

Sebastian Schaub, DVM
Dr. med. vet. DipECVDI

HOSPITAL NAME

Neel Veterinary
Hospital

REFERRING VET

Dr. Deepan Kishore

INVOICE

50792

DATE

3-7-22