



PATIENT

Miles Pellegrino

PRESENTING CLINICAL SIGNS

Limping right front leg swelling at right shoulder joint.

SPECIES

Canine

RADIOGRAPHIC STUDY OF THE SHOULDER JOINTS

Radiographs of the right shoulder joint in two orthogonal imaging planes are provided for review.

BREED

Retriever Labrador
Mix

RADIOGRAPHIC FINDINGS

The right proximal third of the humerus presents an ill-defined zone with permeative osteolysis and advanced amorphous periosteal new bone formation. A mild to moderate circumferential soft tissue swelling is seen level with the proximal right humerus.

RADIOGRAPHIC DIAGNOSIS

- Monostotic aggressive mixed osteolytic and osteoproliferative lesion right proximal humerus

SEX

MN

INTERPRETATION OF THE FINDINGS & FURTHER RECOMMENDATIONS

The aggressive bone lesion of the humerus is consistent with primary osseous neoplasia, such as osteosarcoma, chondrosarcoma, fibrosarcoma. FNA sampling or bone biopsy can be used to confirm the diagnosis.

AGE

13 Years

Consider full tumor staging.

INTERPRETED BY

Sebastian Schaub, DVM
Dr. med. vet. DipECVDI

HOSPITAL NAME

The Collegeway
Animal Hospital

REFERRING VET

Dr. Ehab Hanna

INVOICE

57078

DATE

3-6-23



PATIENT

Miles Pellegrino

SPECIES

Canine

BREED

Retriever Labrador
Mix

SEX

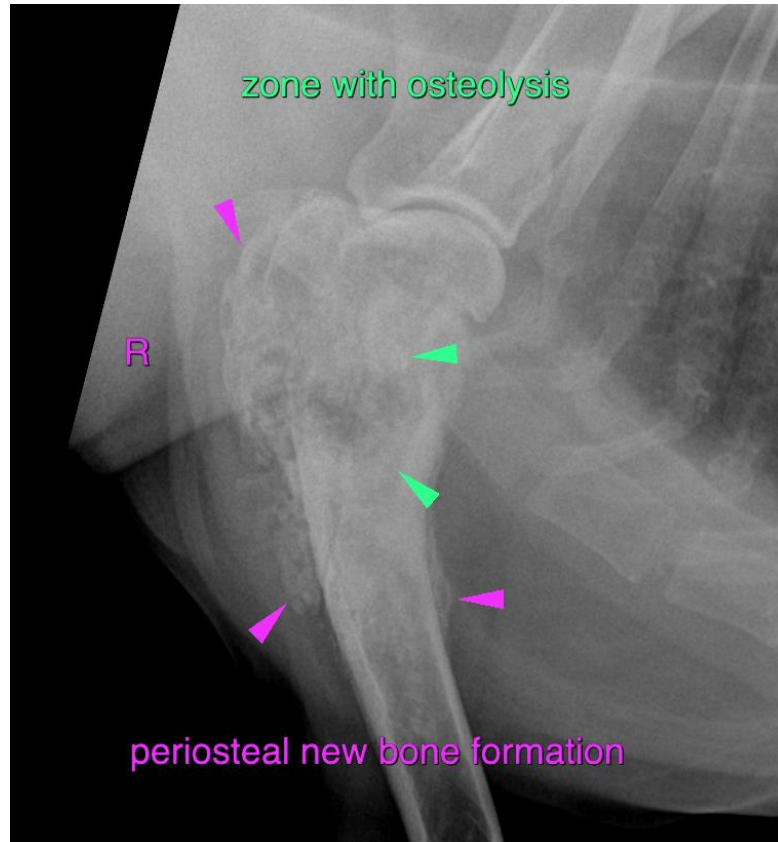
MN

AGE

13 Years

INTERPRETED BY

Sebastian Schaub, DVM
Dr. med. vet. DipECVDI



HOSPITAL NAME

The Collegeway
Animal Hospital

REFERRING VET

Dr. Ehab Hanna

INVOICE

57078

DATE

3-6-23

The information and recommendations provided are based on the images presented by the referring veterinarian/sonographer. No evaluation can be communicated regarding pathology that was not visible in the image/video clips provided.

Thank you for this referral. If the clinical or image interpretation does not parallel your findings or if I can be of any further assistance please contact me.

Sebastian Schaub, Sebastian Schaub, DVM, Dr. med. vet. DipECVDI
sebast.schaub@gmail.com