



**PATIENT**

Bella Yermakova

**PRESENTING CLINICAL SIGNS**

Hx of gagging, not able to eat for the last week or so. No improvement with antibiotics and Cerenia. Seems to want to eat, but unable to  
Abnormal PE/Chem/CBC/UA Results: CBC and chemistry results WNL Throat/laryngeal area feels swollen, painful, and dog starts gagging when palpated

**SPECIES**

Canine

**RADIOGRAPHIC STUDY OF THE NECK**

Radiographs of the neck in two orthogonal imaging planes are provided for review.

**BREED**

Toy Poodle

**RADIOGRAPHIC FINDINGS**

The intervertebral disc space C3/C4 is mild to moderately narrowed.

**SEX**

FS

In the VD view, a mild left sided deviation of the most cranial tracheal segment is noted.

The remainder of the osseous and soft tissue structures of the neck are within normal limits.

**RADIOGRAPHIC DIAGNOSIS**

- Mild left sided deviation of cranial tracheal segment
- Discopathy C3/C4

**AGE**

9 Years

**INTERPRETED BY**

Sebastian Schaub, DVM  
Dr. med. vet. DipECVDI

**INTERPRETATION OF THE FINDINGS & FURTHER RECOMMENDATIONS**

The mild left sided deviation of the cranial trachea segment can be caused by the mild rotation of the skull. A soft tissue swelling – such as lymphadenopathy med retropharyngeal lymph node – is a consideration but no overt mass effect or swelling is appreciated in the lateral views.

**HOSPITAL NAME**

Balmy Beach Pet  
Hospital

An ultrasound examination of the neck can be considered for further evaluation of the retropharyngeal structures. Consider visual evaluation of the pharyngeal region as well to rule out trapped foreign material (e.g. blade of grass).

**REFERRING VET**

Dr. Singh

**INVOICE**

50754

**DATE**

3-6-22



**PATIENT**

Bella Yermakova

**SPECIES**

Canine

**BREED**

Toy Poodle

**SEX**

FS

**AGE**

9 Years

**INTERPRETED BY**

Sebastian Schaub, DVM  
Dr. med. vet. DipECVDI

**HOSPITAL NAME**

Balmy Beach Pet  
Hospital

**REFERRING VET**

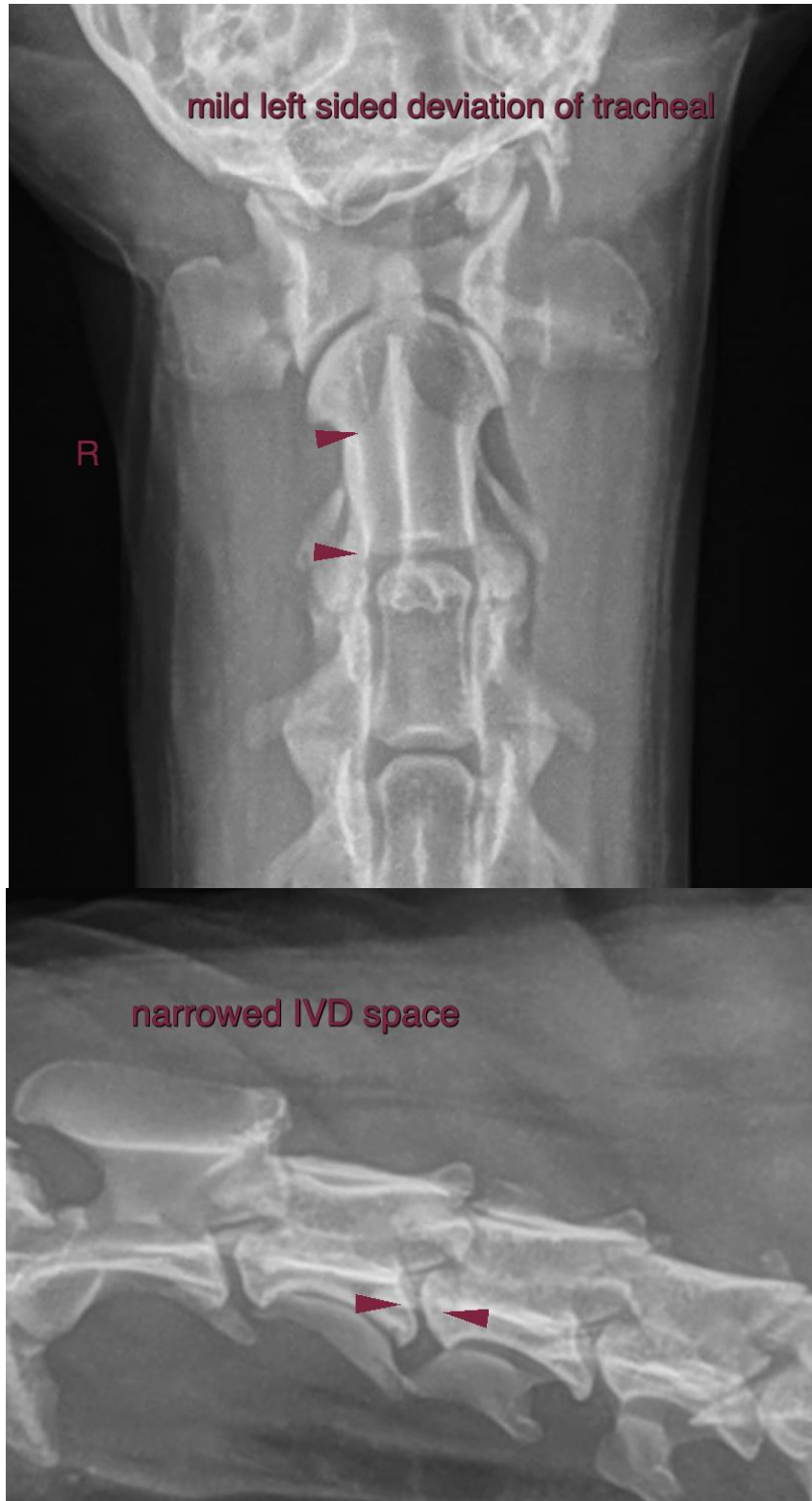
Dr. Singh

**INVOICE**

50754

**DATE**

3-6-22





**PATIENT**

Bella Yermakova

**SPECIES**

Canine

**BREED**

Toy Poodle

**SEX**

FS

**AGE**

9 Years

**INTERPRETED BY**

Sebastian Schaub, DVM  
Dr. med. vet. DipECVDI

**HOSPITAL NAME**

Balmy Beach Pet  
Hospital

**REFERRING VET**

Dr. Singh

**INVOICE**

50754

**DATE**

3-6-22

The information and recommendations provided are based on the images presented by the referring veterinarian/sonographer. No evaluation can be communicated regarding pathology that was not visible in the image/video clips provided.

Thank you for this referral. If the clinical or image interpretation does not parallel your findings or if I can be of any further assistance please contact me.

**Sebastian Schaub**, Sebastian Schaub, DVM, Dr. med. vet. DipECVDI  
sebast.schaub@gmail.com