



PATIENT

Lola Christie

SPECIES

Canine

BREED

Chihuahua X JRT

SEX

FS

AGE

5Y

WEIGHT

6.4kg

INTERPRETED BY

Sebastian Schaub, DVM
Dr. med. vet.
DipECVDI

IMAGING PERFORMED BY

CJ, VH

HOSPITAL NAME

The Collegeway Animal
Hospital

REFERRING VET

Dr. Ehab Hanna

INVOICE

74075

DATE

3-5-26

PRESENTING CLINICAL SIGNS

- was recently hospitalized for pancreatitis
- still having some pain in the abdomen and not eating
- Also especially painful around the spine
- suspect something in the lumbar region

RADIOGRAPHIC STUDY OF THE ABDOMEN & LUMBAR SPINE

Radiographs of the abdomen and lumbar spine in three imaging planes are provided for review.

RADIOGRAPHIC FINDINGS

The surrounding bony structures are within normal limits. The intervertebral disc spaces along the lumbar spine present the expected width, unremarkable.

No abnormalities of the extraabdominal soft tissues are noted. The abdominal wall is smooth and thin.

The serosal detail is maintained throughout the peritoneal and retroperitoneal space.

The liver is appropriate in position, size and presents uniform opacity.

The splenic head is in the anticipated position and within normal limits for size and opacity. The splenic body and tail are considered normal for position, size, shape and opacity.

Both kidneys are seen and present with normal size, shape, delineation and opacity. The urinary bladder is in its anticipated position. No radiopaque calculi are noted throughout the upper and lower urinary tract.

The stomach is in its anticipated position and presents normal content.

The small intestinal loops are of even diameter and non-dilated, a small amount of gas is seen within the small intestinal loops and considered within normal limits.

The colon is seen in the expected position and presents with appropriate content.

RADIOGRAPHIC DIAGNOSIS

- Normal abdomen
- Normal lumbar spine

INTERPRETATION OF THE FINDINGS & FURTHER RECOMMENDATIONS

The radiographic study reveals no abnormalities and an underlying cause for the described pain cannot be specified.



PATIENT

Lola Christie

SPECIES

Canine

BREED

Chihuahua X JRT

SEX

FS

AGE

5Y

WEIGHT

6.4kg

INTERPRETED BY

Sebastian Schaub, DVM
Dr. med. vet.
DipECVDI

IMAGING PERFORMED BY

CJ, VH

HOSPITAL NAME

The Collegeway Animal
Hospital

REFERRING VET

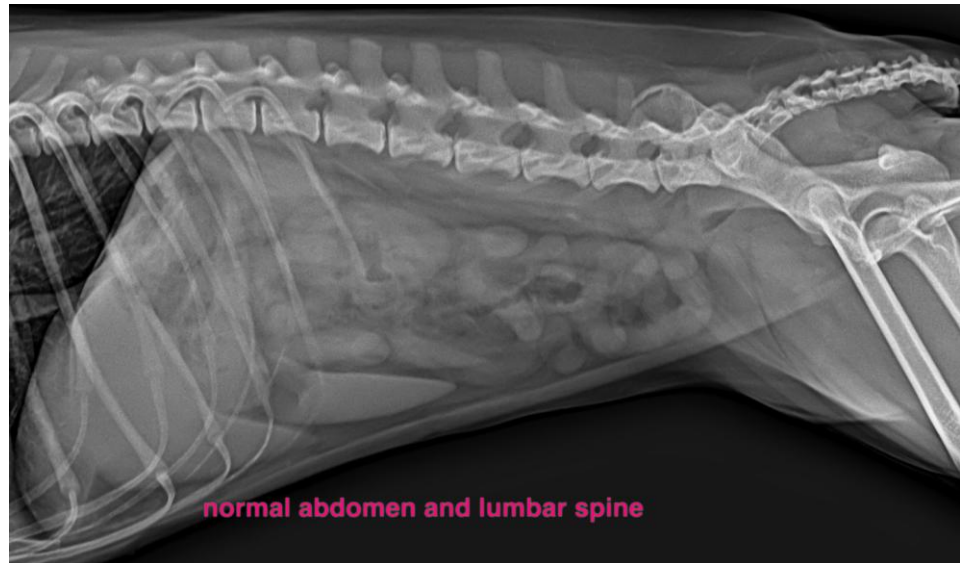
Dr. Ehab Hanna

INVOICE

74075

DATE

3-5-26



The information and recommendations provided are based on the images presented by the referring veterinarian/sonographer. No evaluation can be communicated regarding pathology that was not visible in the image/video clips provided.

Thank you for this referral. If the clinical or image interpretation does not parallel your findings or if I can be of any further assistance please contact me.

Sebastian Schaub, Sebastian Schaub, DVM, Dr. med. vet. DipECVDI
info@sonopath.com