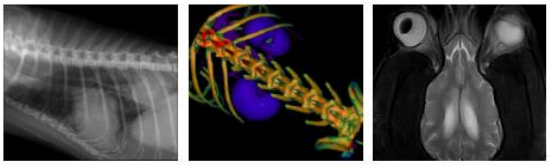

SonoPath.com
1-800-838-4268 info@sonopath.com

PATIENT

Bogie Jackson

SPECIES

Feline

BREED

DMH

SEX

MC

AGE

12 Years

INTERPRETED BY

Sebastian Schaub, DVM
Dr. med. vet. DipECVDI

HOSPITAL NAME

Animal Emergency Hospital Deland

REFERRING VET

Dr. Johnson

INVOICE

57049

DATE

3-5-23

PRESENTING CLINICAL SIGNS

Presented to rDVM 3/2/23 for swelling of the right eye. rDVM administered onsior and convenia. Owner has not seen any improvement. Concern for mass in the oral cavity that is putting pressure on the right eye.
Abnormal PE/Chem/CBC/UA Results: Stress Leukogram Lactate 4.58 Glucose 193

COMPUTED TOMOGRAPHY OF THE SKULL, THORAX AND ABDOMEN

A high resolution pre- and post-contrast CT study of the skull and abdomen and a post-contrast CT study of the thorax are provided for review.

COMPUTED TOMOGRAPHIC FINDINGS

Skull

The pictured parts of the dentition are complete and unremarkable in all jaw quadrants.

Centered on the ramus of the right mandible, an expansile, amorphous ossifying lesion is seen, measuring approximately 2.4 x 2.0 x 3.8 cm. The coronoid process of the ramus of the right mandible presents permeative osteolytic lesions. Immature periosteal new bone formation are seen along the ventral aspects of the ramus of the right mandible. In the rostral aspect the surrounding soft tissue component of the ossifying mass is extending up to the level of triadan 108 of the maxillary bone and triadan 409 along the mandible. Post contrast administration, the ossifying mass of the right ramus of the mandible has a heterogeneous contrast enhancement pattern. The right ocular bulb is deviated rostrally & dorsally and distorted by the mass effect.

The nasal cavity presents the expected aerated spaces between thin & even conchae and turbinates with smooth mucosal lining.

Both temporomandibular joints present congruent joint spaces with even subchondral bone surfaces and are considered within normal limits.

Both tympanic bullae are aerated, the mucosal lining is not seen, the bony wall is smooth and thin. The external ear canals are within normal limits.

The brain presents no deviation from normal anatomy and symmetry. The brain parenchyma is homogeneous and within normal limits for attenuation and distribution of contrast enhancement. The ventricular system is non-dilated and symmetric.

The submandibular and medial retropharyngeal lymph nodes are small and elongated with a normal short-to-long-axis-ratio is < 0.5, the attenuation and contrast enhancement pattern is uniform.

Thorax

Multifocal spondylosis formation is seen along the thoracolumbar junction.

The sternal, cranial mediastinal and tracheobronchial lymph nodes are small elongated with a normal short-to-long-axis-ratio is < 0.5, the attenuation and contrast enhancement pattern is uniform and considered within normal limits.

The cardiovascular structures including the pulmonary vasculature are within normal limits.

In the right cranial lung lobe, an irregular contrast enhancing mass is centered on the first degree bronchus an irregular shaped, uniform soft tissue attenuating and heterogeneous contrast

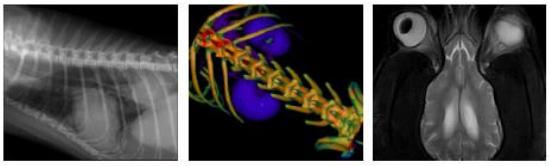

SonoPath.com
1-800-838-4268 info@sonopath.com

PATIENT

Bogie Jackson

SPECIES

Feline

BREED

DMH

SEX

MC

AGE

12 Years

INTERPRETED BY

Sebastian Schaub, DVM
Dr. med. vet. DipECVDI

HOSPITAL NAME

Animal Emergency Hospital Deland

REFERRING VET

Dr. Johnson

INVOICE

57049

DATE

3-5-23

enhancing mass, measuring 1.3 x 1.2 x 1.3 cm is seen, causing segmental bronchial obstruction. The mass in the right cranial lung lobe presents focal punctuate mineralization.

Small incidental gas pockets are seen within the esophageal lumen, there is no evidence of abnormal dilation.

Abdomen

The serosal fat presents normal attenuation behavior. There is no evidence of peritoneal effusion or peritonitis.

Both kidneys present within normal limits for size, shape and organ architecture. After contrast administration a bilaterally symmetric and uniform nephro- and pyelogram is noted.

The adrenal glands are within normal limits for size, shape and organ architecture.

The liver presents with normal shape, even surface, uniformly attenuating parenchyma and homogeneous contrast enhancement, unremarkable.

In the body of the spleen, a nodular, heterogeneous contrast enhancing lesions is seen, mildly protruding beyond the splenic surface, measuring 7 mm in diameter.

The pancreas is evenly contoured, the pancreatic parenchyma is homogeneous and presents uniform contrast enhancement.

The position, delineation, wall and content of the gastrointestinal tract are considered within normal limits throughout.

COMPUTED TOMOGRAPHIC DIAGNOSIS

- Monostotic aggressive mixed osteolytic and osteoproliferative lesion centered on the ramus of the right mandible
- Secondary right sided exophthalmos
- Soft tissue mass right cranial lung lobe, centered on the first degree bronchus
- Splenic nodule
- Spondylosis deformans thoracolumbar junction

INTERPRETATION OF THE FINDINGS & FURTHER RECOMMENDATIONS

The findings of the CT study are consistent with primary osseous neoplasia, originating from the right ramus of the mandible – such as osteosarcoma, chondrosarcoma, fibrosarcoma, other. The mass is exerting a mass effect on the right ocular bulb, explaining the presenting clinical signs. FNA sampling might be performed for further definition. The chances of palliative radiation therapy might be discussed with oncologist.

The pulmonary mass of the right cranial lung lobe is concerning for second entity and primary pulmonary neoplasia is considered likely – e.g. bronchogenic carcinoma.

The splenic nodule is not specific and nodular hyperplasia or neoplastic infiltration (primary versus secondary) are potentials. Ultrasound guided FNA sampling can be used as advanced minimally invasive diagnostic tool.

SonoPath Teleradiology

EDUCATIONAL TELECONSULTATION SERVICES™

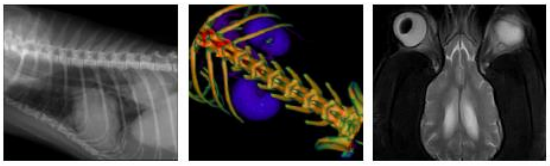

SonoPath.com
1-800-838-4268 info@sonopath.com

PATIENT

Bogie Jackson

SPECIES

Feline

BREED

DMH

SEX

MC

AGE

12 Years

INTERPRETED BY

Sebastian Schaub, DVM
Dr. med. vet. DipECVDI

HOSPITAL NAME

Animal Emergency Hospital Deland

REFERRING VET

Dr. Johnson

INVOICE

57049

DATE

3-5-23

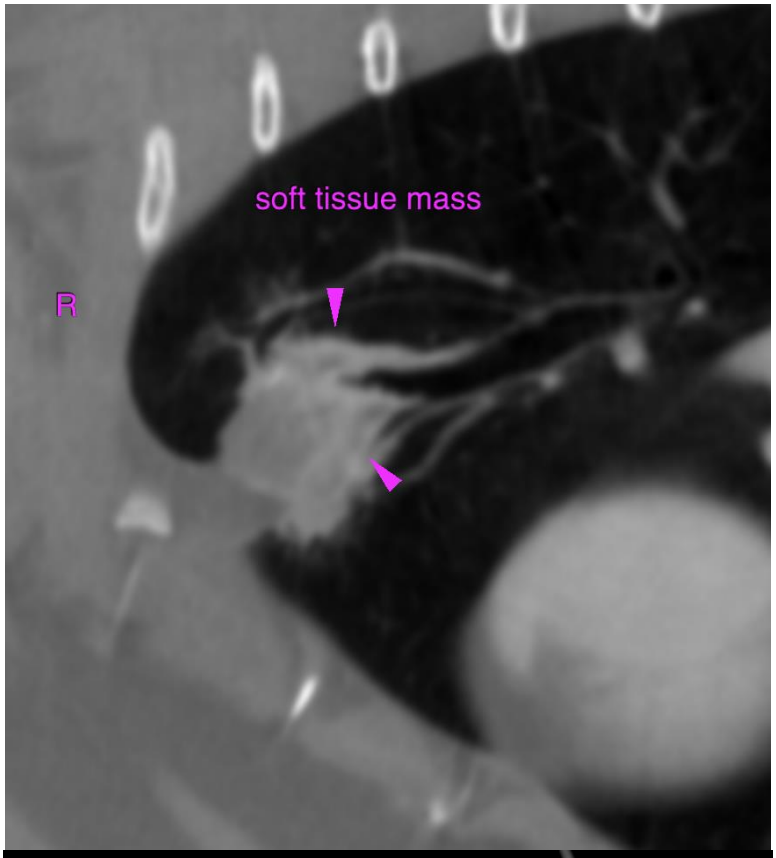

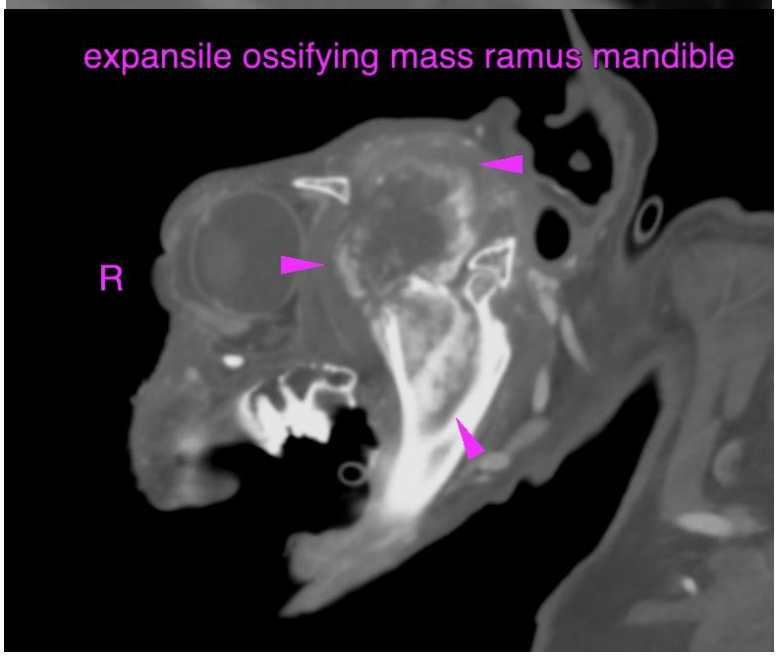

SonoPath Teleradiology

EDUCATIONAL TELECONSULTATION SERVICES™

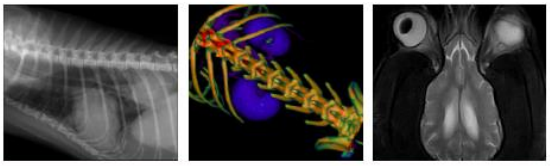

SonoPath.com
1-800-838-4268 info@sonopath.com

PATIENT

Bogie Jackson

SPECIES

Feline

BREED

DMH

SEX

MC

AGE

12 Years

INTERPRETED BY

Sebastian Schaub, DVM
Dr. med. vet. DipECVDI

HOSPITAL NAME

Animal Emergency
Hospital Deland

REFERRING VET

Dr. Johnson

INVOICE

57049

DATE

3-5-23

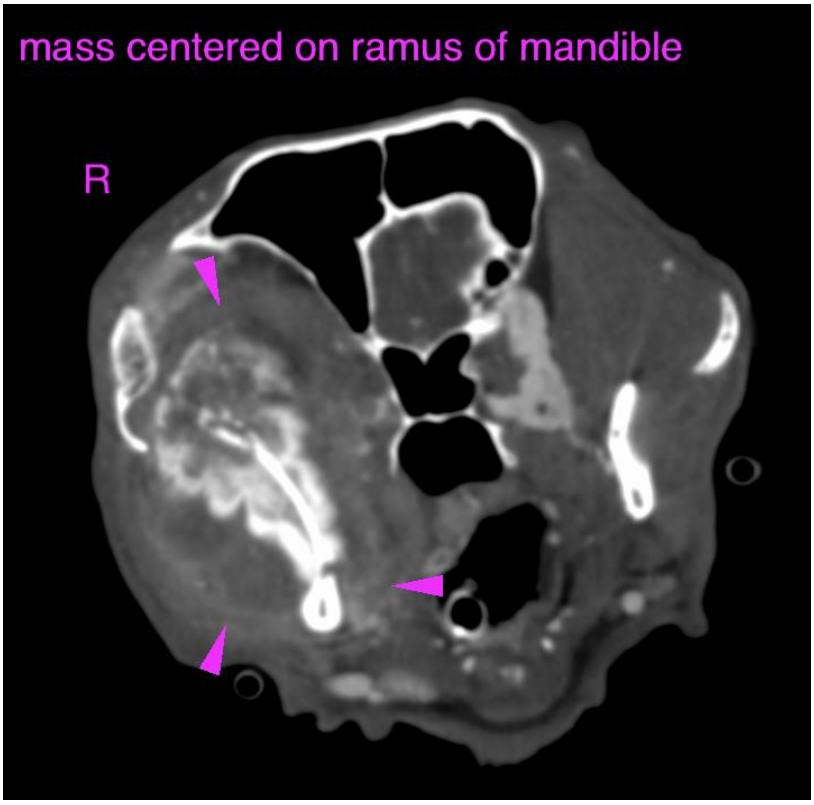

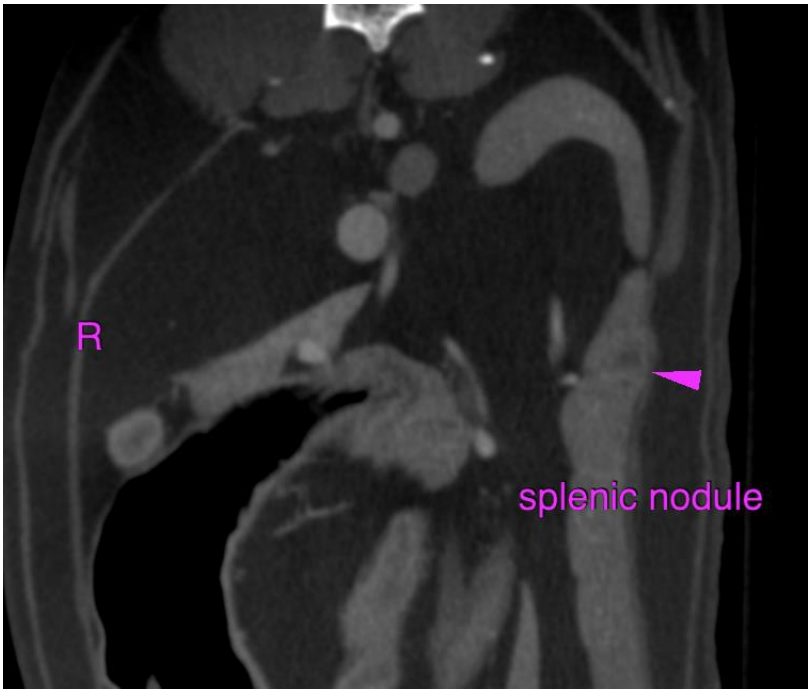

SonoPath Teleradiology

EDUCATIONAL TELECONSULTATION SERVICES™

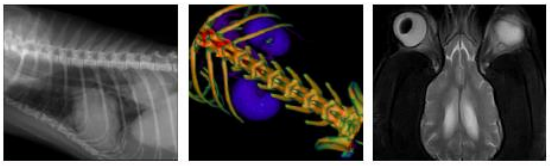

SonoPath.com
1-800-838-4268 info@sonopath.com

PATIENT

Bogie Jackson

SPECIES

Feline

BREED

DMH

SEX

MC

AGE

12 Years

INTERPRETED BY

Sebastian Schaub, DVM
Dr. med. vet. DipECVDI

HOSPITAL NAME

Animal Emergency
Hospital Deland

REFERRING VET

Dr. Johnson

INVOICE

57049

DATE

3-5-23

The information and recommendations provided are based on the images presented by the referring veterinarian/sonographer. No evaluation can be communicated regarding pathology that was not visible in the image/video clips provided.

Thank you for this referral. If the clinical or image interpretation does not parallel your findings or if I can be of any further assistance please contact me.

Sebastian Schaub, Sebastian Schaub, DVM, Dr. med. vet. DipECVDI
sebast.schaub@gmail.com