



PATIENT PRESENTING CLINICAL SIGNS

Luna Dennis Patient presented for increased panting/stertor with vomiting mucus episodes. Difficult to determine if crackles or referred upper airway sounds

SPECIES RADIOGRAPHIC STUDY OF THE THORAX

Canine Radiographs of the thorax in three imaging planes are provided for review.

RADIOGRAPHIC FINDINGS

The body condition score is 7-8/9.

BREED

English Bulldog Multiple hemivertebra are seen along the thoracic spine with accompanying kyphosis of the thoracic spine.

SEX

The extrathoracic soft tissues present homogeneous without abnormalities.

FS

The heart is of normal size and shape, there is no evidence of cardiac chamber or vascular enlargement. The pulmonary vasculature is within normal limits.

AGE

2

The mediastinum contains a moderate amount of fat and is moderately widened. The intrathoracic segment of the trachea presents a mild to moderate right sided bending level with the cranial mediastinum – considered as normal variant in the brachiocephalic breed.

INTERPRETED BY

Sebastian Schaub, DVM
Dr. med. vet. DipECVDI

The tracheal diameter is mildly decreased.

Mild peribronchial cuffing is noted.

HOSPITAL NAME

Boca Park Animal
Hospital

The lung parenchyma presents the expected architecture and opacity; the intrapulmonary vascular branching is seen up to the third order lung vessels.

The diaphragm is well delineated with even surface and the expected mild cranial bulging of the diaphragmatic cupola.

REFERRING VET

Dr. Corinna Gorgon

RADIOGRAPHIC DIAGNOSIS

- Obesity
- Mild bronchial lung pattern
- Mild tracheal hypoplasia
- Multiple hemivertebra thoracic spine with kyphosis of the thoracic spine

INVOICE

50763

INTERPRETATION OF THE FINDINGS & FURTHER RECOMMENDATIONS

The bronchial lung pattern is suggestive for bronchitis – primary inflammatory origin (e.g. eosinophilic, neutrophilic, mixed) is considered more likely than infectious causes (e.g. viral, bacterial, parasitic). However, rule out brachycephalic obstructive airway syndrome as main underlying cause for the described clinical signs – that might be accentuated by mild tracheal hypoplasia.

DATE

3-5-22

Consider complementing treatment by gastric protection therapy.



PATIENT

Luna Dennis

SPECIES

Canine

BREED

English Bulldog

SEX

FS

AGE

2

INTERPRETED BY

Sebastian Schaub, DVM
Dr. med. vet. DipECVDI

HOSPITAL NAME

Boca Park Animal
Hospital

REFERRING VET

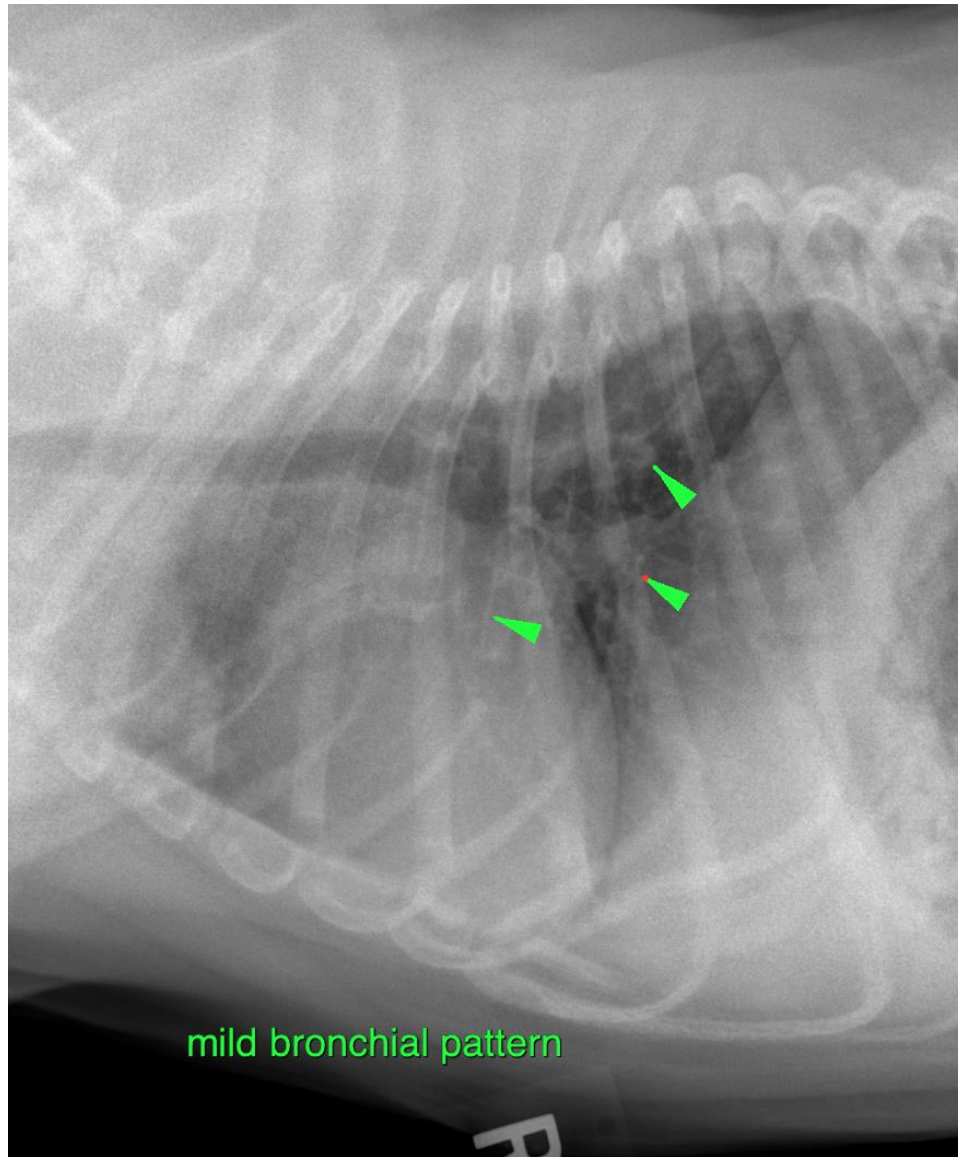
Dr. Corinna Gorgon

INVOICE

50763

DATE

3-5-22



The information and recommendations provided are based on the images presented by the referring veterinarian/sonographer. No evaluation can be communicated regarding pathology that was not visible in the image/video clips provided.

Thank you for this referral. If the clinical or image interpretation does not parallel your findings or if I can be of any further assistance please contact me.

Sebastian Schaub, Sebastian Schaub, DVM, Dr. med. vet. DipECVDI
sebast.schaub@gmail.com