

**PATIENT PRESENTING CLINICAL SIGNS**

Riley Scott History: Two-year history of nasal discharge, epistaxis and excessive sneezing. Seems to improve while on antibiotics but then quickly recurs.

**SPECIES COMPUTED TOMOGRAPHIC STUDY OF THE SKULL**

Feline A high resolution pre- and post-contrast CT study of the skull is provided for review.

**COMPUTED TOMOGRAPHIC FINDINGS****BREED**

Ragdoll Triadan 109, 206 and 306 are absent.

A moderate amount of fluid attenuating material is attached to the nasal mucosal lining. Moderate destruction of the nasal conchal structures is present.

**SEX**

Neutered Male Both temporomandibular joints present congruent joint spaces with even subchondral bone surfaces and are considered within normal limits.

**AGE**

12 Years

Both tympanic bullae are aerated, the mucosal lining is not seen, the bony wall is smooth and thin. The external ear canals are within normal limits.

The brain presents no deviation from normal anatomy and symmetry. The brain parenchyma is homogeneous and within normal limits for attenuation and distribution of contrast enhancement. The ventricular system is non-dilated and symmetric.

**INTERPRETED BY**

Sebastian Schaub, DVM  
Dr. med. vet. DipECVDI

The submandibular and medial retropharyngeal lymph nodes are small and elongated with a normal short-to-long-axis-ratio is  $< 0.5$ , the attenuation and contrast enhancement pattern is uniform.

**HOSPITAL NAME**

Mobile Pet Imaging  
CFL

**COMPUTED TOMOGRAPHIC DIAGNOSIS**

- Destructive rhinitis
- Absent triadan 109, 206 and 306

**INTERPRETATION OF THE FINDINGS & FURTHER RECOMMENDATIONS****REFERRING VET**

Dr. Borecky

The findings are consistent with chronic destructive rhinitis. The causative agent is most likely primary viral with bacterial superinfection. Even though unlikely there is a small chance of emerging fungal (cryptococcal) superinfection.

**INVOICE**

14495

Rhinoscopy with biopsy and samples for microbial cultures is recommended. In cases of chronic rhinosinusitis, clinical signs are prone to reoccur.

**DATE**

3/31/22



**PATIENT**

Riley Scott

**SPECIES**

Feline

**BREED**

Ragdoll

**SEX**

Neutered Male

**AGE**

12 Years

**INTERPRETED BY**

Sebastian Schaub, DVM  
Dr. med. vet. DipECVDI

**HOSPITAL NAME**

Mobile Pet Imaging  
CFL

**REFERRING VET**

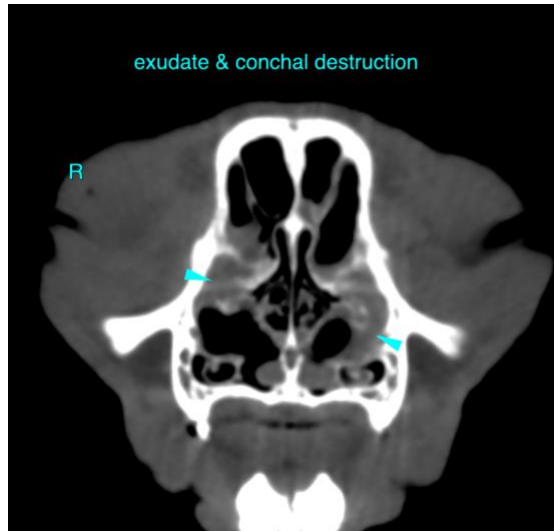
Dr. Borecky

**INVOICE**

14495

**DATE**

3/31/22



The information and recommendations provided are based on the images presented by the referring veterinarian/sonographer. No evaluation can be communicated regarding pathology that was not visible in the image/video clips provided.

Thank you for this referral. If the clinical or image interpretation does not parallel your findings or if I can be of any further assistance please contact me.

**Sebastian Schaub**, Sebastian Schaub, DVM, Dr. med. vet. DipECVDI  
sebast.schaub@gmail.com