



**PATIENT PRESENTING CLINICAL SIGNS**

**Luna Munoz** History: Pet is here because she can't put weight on left paw, and she can't breath well, choking a lot looks like asthma. O gives the "natural medication for allergy" No D/V/C/S E/D/U/D ok O: BC 8/9, BAR, m.m-pink, teeth- tartar, OU- corneal pigmentation, OS- corneal opacity and dry mucoid discharge, H/L, Abdo, U/G, skin and coat, M/S- lame LH 2/5 A: R/O KCS Cough- respiratory vs Cardiac vs others Severe overweight R/O hypothyroidism sprain vs others

**SPECIES**

Canine

**RADIOGRAPHIC STUDY OF THE PELVIS AND STIFLE JOINTS**

**BREED**

Radiographs of the pelvis and left stifle joint are provided for review.

Mixed Shih Tzu

**RADIOGRAPHIC FINDINGS**

**SEX**

Female

A wet fur artefact is noted along the hind limbs.

The periarticular bones of the left coxofemoral joint presents moderate osteophyte new bone formation. The left acetabular groove is shallow and the center of the left femoral head is lateral to the dorsal acetabular rim.

**AGE**

8 Years

The right coxofemoral joint appears normal.

The patella of both stifle joints is superimposed on the medial aspect of the medial femoral condyle bilaterally.

**INTERPRETED BY**

Sebastian Schaub,  
DVM Dr. med. vet.  
DipECVDI

The periarticular bones of the the left stifle joint present mild to moderate osteophyte new bone formation and a mild intracapsular soft tissue swelling is present. The left talocrural joint presents with a moderate periarticular swelling.

**RADIOGRAPHIC DIAGNOSIS**

**HOSPITAL NAME**

Animal Paradise  
Hospital

- Suspect articular swelling left tibiotarsal joint
- Bilateral medial patellar luxation
- Mild to moderate degenerative osteoarthritis left stifle joint
- Mild articular swelling left stifle joint
- Degenerative osteoarthritis left coxofemoral joint, due to hip dysplasia

**REFERRING VET**

Dr. Elshafie

**INTERPRETATION OF THE FINDINGS & FURTHER RECOMMENDATIONS**

There is a moderate periarticular swelling of the left talocrural joint, check if the diagnosis can be confirmed in the clinical examination – if so rule out degenerative effusion, trauma or arthritis (immune mediated versus infectious) by a synovial tap.

**INVOICE**

14493

Due to the age of the patient, the clinical relevance of the medial patellar luxation is unclear.

**DATE**

3/31/22



**PATIENT**

Luna Munoz

The left sided degenerative osteoarthritis with concomitant joint effusion can be a sequela to (partial) rupture of the cranial cruciate ligament with or without meniscal disease. A positive drawer sign or tibial compression test under general anesthesia can be used to rule in/out the diagnosis.

**SPECIES**

Canine

**BREED**

Mixed Shih Tzu

**SEX**

Female

**AGE**

8 Years

**INTERPRETED BY**

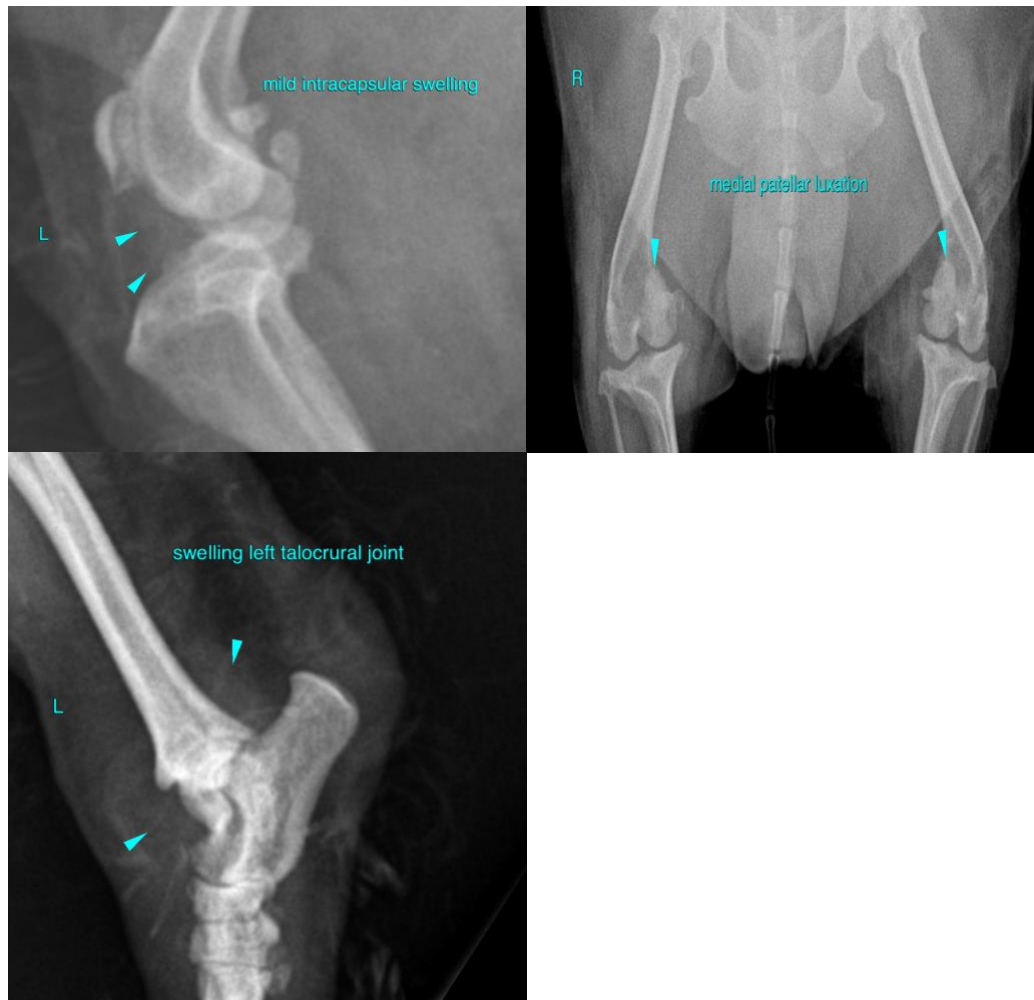
Sebastian Schaub,  
DVM Dr. med. vet.  
DipECVDI

**HOSPITAL NAME**

Animal Paradise  
Hospital

**REFERRING VET**

Dr. Elshafie



**The information and recommendations provided are based on the images presented by the referring veterinarian/sonographer. No evaluation can be communicated regarding pathology that was not visible in the image/video clips provided.**

**INVOICE**

14493

Thank you for this referral. If the clinical or image interpretation does not parallel your findings or if I can be of any further assistance please contact me.

**DATE**

3/31/22



**PATIENT**

Luna Munoz

**Sebastian Schaub**, Sebastian Schaub, DVM, Dr. med. vet. DipECVDI  
sebast.schaub@gmail.com

**SPECIES**

Canine

**BREED**

Mixed Shih Tzu

**SEX**

Female

**AGE**

8 Years

**INTERPRETED BY**

Sebastian Schaub,  
DVM Dr. med. vet.  
DipECVDI

**HOSPITAL NAME**

Animal Paradise  
Hospital

**REFERRING VET**

Dr. Elshafie

**INVOICE**

14493

**DATE**

3/31/22