



PATIENT

Alaska Kohan

SPECIES

Canine

BREED

Poodle X

SEX

Female Spayed

AGE

12Y

WEIGHT

5.39kg

INTERPRETED BY

Sebastian Schaub, DVM
Dr. med. vet.
DipECVDI

IMAGING PERFORMED BY

AS/JS

HOSPITAL NAME

Green Dog Dental and
Wellness

REFERRING VET

Dr. Candice Habawel

INVOICE

74383

DATE

3-30-26

PRESENTING CLINICAL SIGNS

- Suspected retained foxtail in nostril following hiking incident on Thursday with ongoing paroxysmal sneezing and pawing at nose.
- - Cardiology evaluation by Dog and Cat Cardio in September 2025 diagnosed ACVIM stage B1 mitral valve disease. Advanced dental procedure performed September 15, 2025 with multiple extractions and two oronasal fistulas.

Abnormal PE/Chem/CBC/UA Results: Lidocaine applied to both nostrils, no superficial foxtails visible approximately 1 cm into both nostrils.

COMPUTED TOMOGRAPHY OF THE SKULL

A high resolution pre- and post-contrast CT study of the skull is provided for review.

COMPUTED TOMOGRAPHIC FINDINGS

Multiple teeth are absent.

The nasal cavity presents the expected aerated spaces between thin & even conchae and turbinates with smooth mucosal lining.

Both temporomandibular joints present congruent joint spaces with even subchondral bone surfaces and are considered within normal limits.

Both tympanic bullae are aerated, the mucosal lining is not seen, the bony wall is smooth and thin. The external ear canals are within normal limits.

The brain presents no deviation from normal anatomy and symmetry. The brain parenchyma is homogeneous and within normal limits for attenuation and distribution of contrast enhancement. The ventricular system is non-dilated and symmetric.

The submandibular and medial retropharyngeal lymph nodes are small and elongated with a normal short-to-long-axis-ratio is < 0.5, the attenuation and contrast enhancement pattern is uniform.

COMPUTED TOMOGRAPHIC DIAGNOSIS

- Multiple absent teeth
- Normal nasal cavity

INTERPRETATION OF THE FINDINGS & FURTHER RECOMMENDATIONS

The CT study reveals no sign of nasal foreign material.



PATIENT

Alaska Kohan

SPECIES

Canine

BREED

Poodle X

SEX

Female Spayed

AGE

12Y

WEIGHT

5.39kg

INTERPRETED BY

Sebastian Schaub, DVM
Dr. med. vet.
DipECVDI

IMAGING PERFORMED BY

AS/JS

HOSPITAL NAME

Green Dog Dental and
Wellness

REFERRING VET

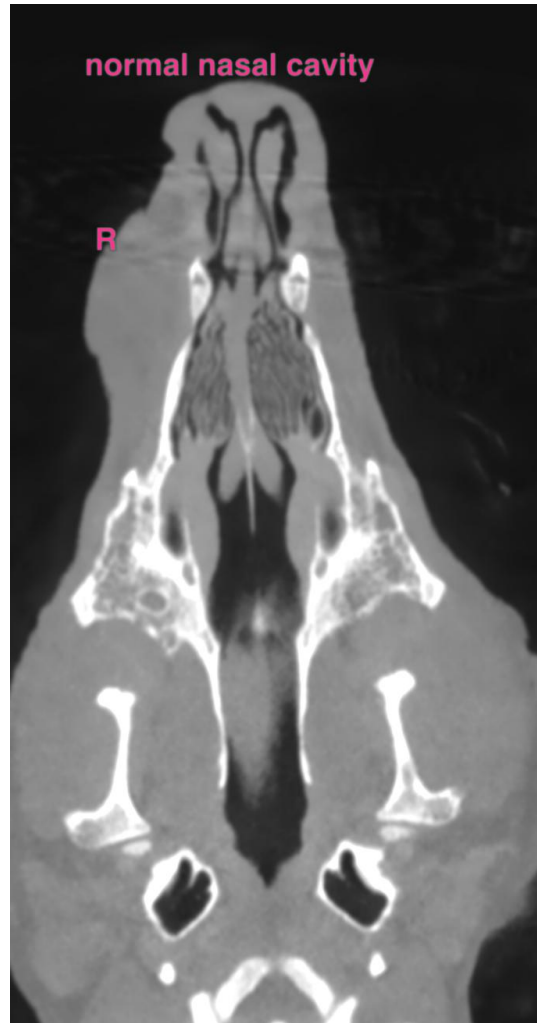
Dr. Candice Habawel

INVOICE

74383

DATE

3-30-26



The information and recommendations provided are based on the images presented by the referring veterinarian/sonographer. No evaluation can be communicated regarding pathology that was not visible in the image/video clips provided.

Thank you for this referral. If the clinical or image interpretation does not parallel your findings or if I can be of any further assistance please contact me.

Sebastian Schaub, Sebastian Schaub, DVM, Dr. med. vet. DipECVDI
info@sonopath.com