



PATIENT PRESENTING CLINICAL SIGNS

Groot Kimme History of intermittent favoring right rear leg for the past few months. Currently receiving 50 mg Carprofen twice daily as needed.
Abnormal PE/Chem/CBC/UA Results: No cranial drawer or tibial thrust under anesthesia. Slight decrease in range of motion of hips. Chemistry/CBC WNL.

SPECIES

Canine

RADIOGRAPHIC STUDY OF THE PELVIS AND STIFLE JOINTS

A radiographs of the pelvis in a ventrodorsal view and radiographs of the stifle joints in two orthogonal imaging planes are provided for review.

BREED

Clumber

RADIOGRAPHIC FINDINGS

The osseous and surrounding soft tissue structures of the pelvis are within normal limits. Both coxofemoral joints present moderate osteophyte new bone formation. The acetabular groove bilaterally is shallow, and the center of the femoral heads is lateral to the dorsal acetabular rim. The joint space of both coxofemoral joints is incongruent.

SEX

MN

The volume of the right thigh musculature is moderately decreased.

AGE

5 Years

The periarticular bones of both stifle joints present very mild osteophyte new bone formation. There is no evidence of intracapsular soft tissue swelling.

RADIOGRAPHIC DIAGNOSIS

INTERPRETED BY

- Degenerative osteoarthritis of both coxofemoral joints due to moderate hip dysplasia
- Disuse atrophy right thigh musculature
- Very mild degenerative osteoarthritis stifle joints bilaterally

Sebastian Schaub, DVM
Dr. med. vet. DipECVDI

HOSPITAL NAME

INTERPRETATION OF THE FINDINGS & FURTHER RECOMMENDATIONS

The degenerative osteoarthritis of both coxofemoral joints is considered as the clinically relevant radiographic finding and can be a source for pain.

Gentle Doctor Animal
Hospital

REFERRING VET

Thorson

INVOICE

57560

DATE

3-30-23



PATIENT

Groot Kimme

SPECIES

Canine

BREED

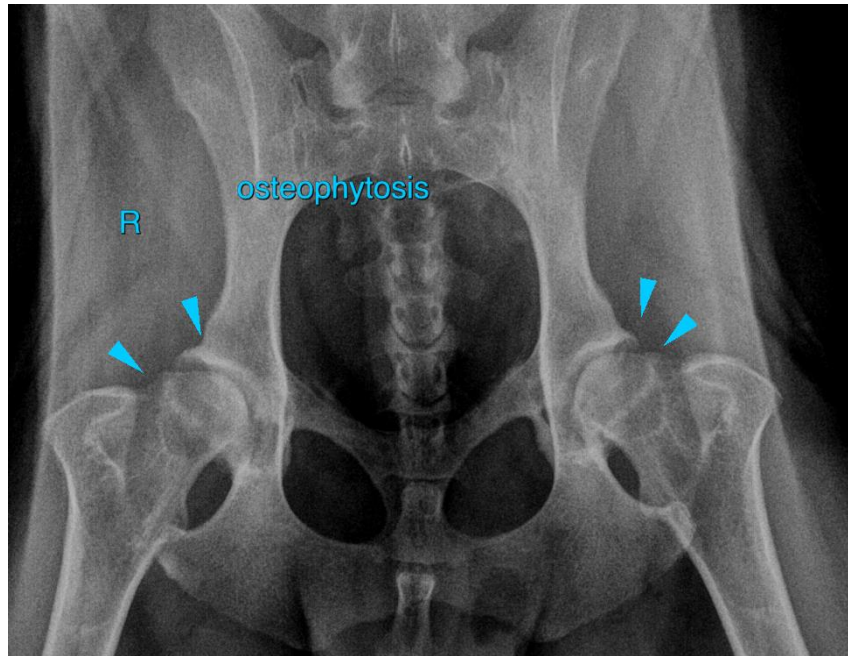
Clumber

SEX

MN

AGE

5 Years



INTERPRETED BY

Sebastian Schaub, DVM
Dr. med. vet. DipECVDI

The information and recommendations provided are based on the images presented by the referring veterinarian/sonographer. No evaluation can be communicated regarding pathology that was not visible in the image/video clips provided.

HOSPITAL NAME

Gentle Doctor Animal
Hospital

Thank you for this referral. If the clinical or image interpretation does not parallel your findings or if I can be of any further assistance please contact me.

Sebastian Schaub, Sebastian Schaub, DVM, Dr. med. vet. DipECVDI
sebast.schaub@gmail.com

REFERRING VET

Thorson

INVOICE

57560

DATE

3-30-23