**PATIENT PRESENTING CLINICAL SIGNS**

Franklin Oberlander additional CT- sent CT of head last March 27 Presented last March 27 for odd seizure-like activity, owner described some are just tremoring, no balance, struggling to walk and some are true seizures. Also with history of ear infections. Has 3 cervical vertebrae fused per owner about 1 year and a half ago.

SPECIES

Canine

COMPUTED TOMOGRAPHY OF THE NECK

A high resolution post-contrast CT study of the neck is provided for review.

BREED COMPUTED TOMOGRAPHIC FINDINGS

Pug

The subchondral bone of the vertebral endplates C3/C4 and C4/C5 present a crescent shaped depression respectively affecting approximately 1/3 of the width of the vertebral endplates and 1/5 of the length of the vertebral bodies respectively. The vertebral endplates C3/C4 and C4/C5 present moderate spondylosis formation.

SEX

MN

Level with the intervertebral disc spaces C2/C3, C5/C6 and C6/C7, mild hyperattenuating material is bulging into the ventral aspect of the vertebral canal, occupying approximately up to 35% of the cross-sectional area of the vertebral canal at the same level – most accentuated level C5/C6.

AGE

The soft tissue structures of the neck present no additional abnormalities.

12 Years, 6 Months

COMPUTED TOMOGRAPHIC DIAGNOSIS**INTERPRETED BY**

Sebastian Schaub, DVM
Dr. med. vet. DipECVDI

- Intervertebral disc protrusion C5/C6 with compressive myelopathy
- Intervertebral disc protrusion C2/C4 and C6/C7 with likely dynamic myelocompression
- Suspect history of ventral slot C3/C4 & C4/C5, secondary spondylosis deformans

INTERPRETATION OF THE FINDINGS & FURTHER RECOMMENDATIONS**HOSPITAL NAME**

State Avenue Vet
Clinic

The intervertebral disc protrusion C5/C6 might be a source for pain and might be associated with neurological deficits as source for the described clinical signs. No additional clinically relevant abnormalities are noted along the thoracic spine.

REFERRING VET

Dr. Raul Casas

INVOICE

57550

DATE

3-30-23



PATIENT

Franklin Oberlander

SPECIES

Canine

BREED

Pug

SEX

MN

AGE

12 Years, 6 Months

INTERPRETED BY

Sebastian Schaub, DVM
Dr. med. vet. DipECVDI

HOSPITAL NAME

State Avenue Vet
Clinic

REFERRING VET

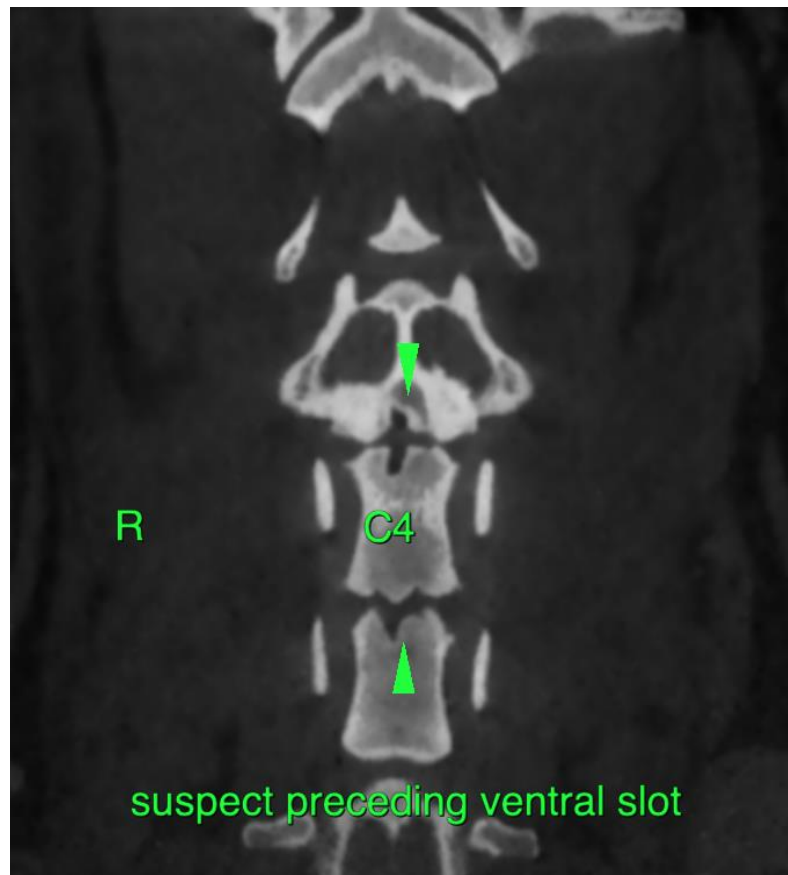
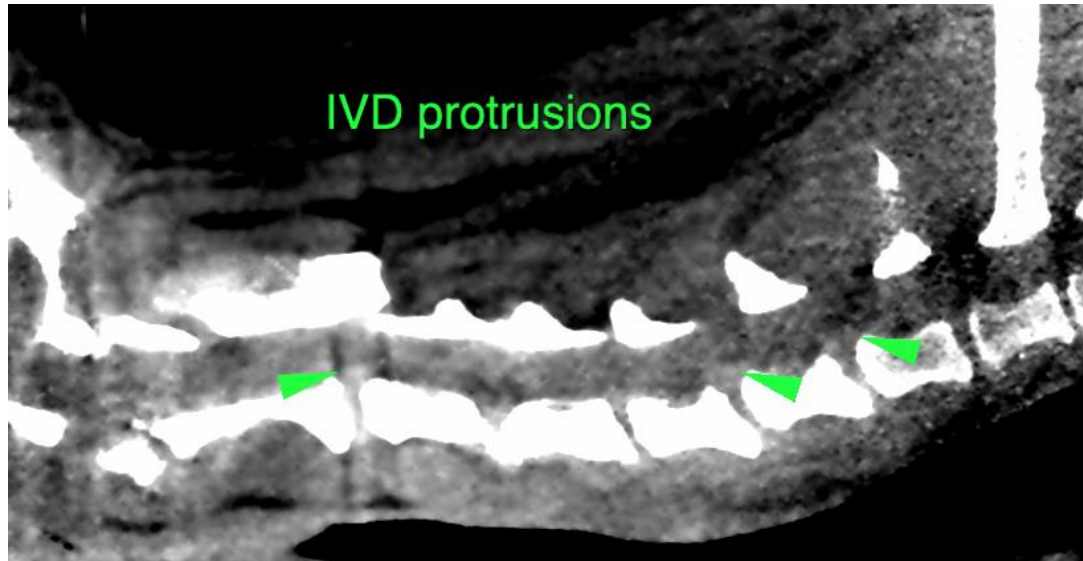
Dr. Raul Casas

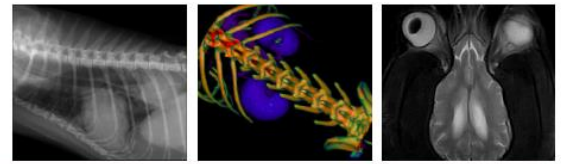
INVOICE

57550

DATE

3-30-23





PATIENT

Franklin Oberlander

SPECIES

Canine

BREED

Pug

SEX

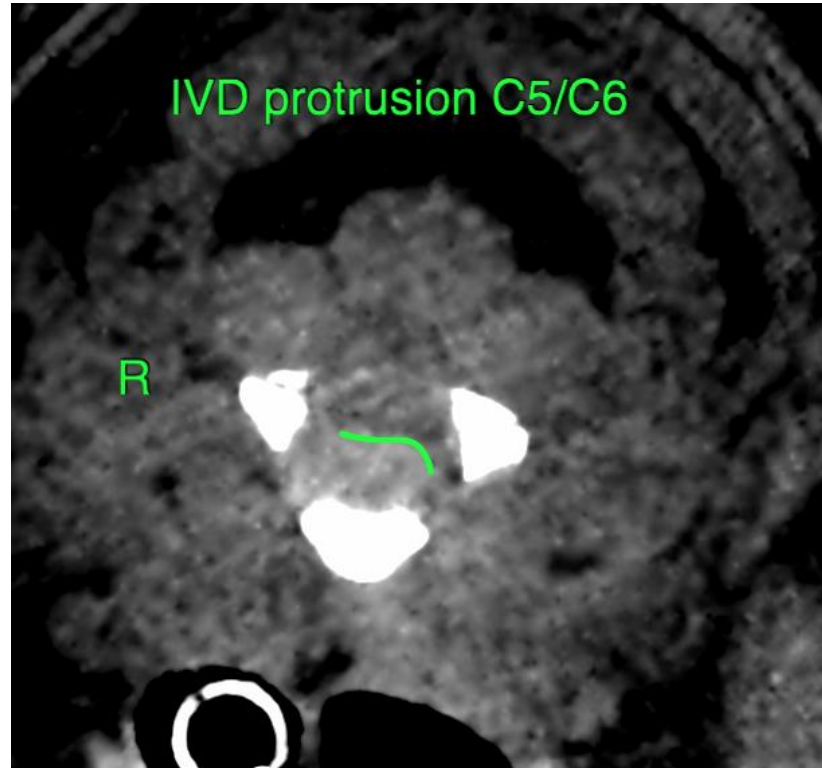
MN

AGE

12 Years, 6 Months

INTERPRETED BY

Sebastian Schaub, DVM
Dr. med. vet. DipECVDI



HOSPITAL NAME

State Avenue Vet
Clinic

REFERRING VET

Dr. Raul Casas

The information and recommendations provided are based on the images presented by the referring veterinarian/sonographer. No evaluation can be communicated regarding pathology that was not visible in the image/video clips provided.

Thank you for this referral. If the clinical or image interpretation does not parallel your findings or if I can be of any further assistance please contact me.

Sebastian Schaub, Sebastian Schaub, DVM, Dr. med. vet. DipECVDI
sebast.schaub@gmail.com

INVOICE

57550

DATE

3-30-23