



PATIENT

Diamond Hancock

PRESENTING CLINICAL SIGNS

For last two weeks Diamond has been very picky about her food owner has tried different diets to get her to eat. Vomiting once a week is normal for her. Currently eating z/d diet, but overall decrease in food intake going on for about two weeks.

SPECIES

Feline

Abnormal PE/Chem/CBC/UA Results: Stage 2 dental disease, dull hair coat, Tender abdomen, mild dehydration, mild elev Pro BNP 101 pmol/L CBC and Chem wnl

RADIOGRAPHIC STUDY OF THE THORAX

BREED

DSH

Radiographs of the abdomen in three imaging planes are provided for review.

RADIOGRAPHIC FINDINGS

SEX

Female Spayed

The surrounding bony structures are within normal limits.

The extrathoracic soft tissues present homogeneous without abnormalities.

The heart is of normal size and shape, there is no evidence of cardiac chamber or vascular enlargement. The pulmonary vasculature is within normal limits.

AGE

12 Years, 3 Months

The trachea is normal in diameter and presents the anticipated course. The luminal outline of the trachea is smooth.

INTERPRETED BY

Sebastian Schaub, DVM
Dr. med. vet. DipECVDI

Mild peribronchial cuffing is noted.

The lung parenchyma presents the expected architecture and opacity; the intrapulmonary vascular branching is seen up to the third order lung vessels.

HOSPITAL NAME

Elizabeth Animal
Hospital

The diaphragm is well delineated with even surface and the expected mild cranial bulging of the diaphragmatic cupola.

RADIOGRAPHIC DIAGNOSIS

- Mild bronchial pattern

REFERRING VET

Dr. Leon Anderson

INTERPRETATION OF THE FINDINGS & FURTHER RECOMMENDATIONS

The radiographic study of the thorax presents without specific abnormalities. The mild bronchial pattern is suggestive for (sub)clinical feline bronchial disease. The cardiac silhouette is likely accentuated by pericardial fat and considered normal.

INVOICE

50696

DATE

3-3-22



PATIENT

Diamond Hancock

SPECIES

Feline

BREED

DSH

SEX

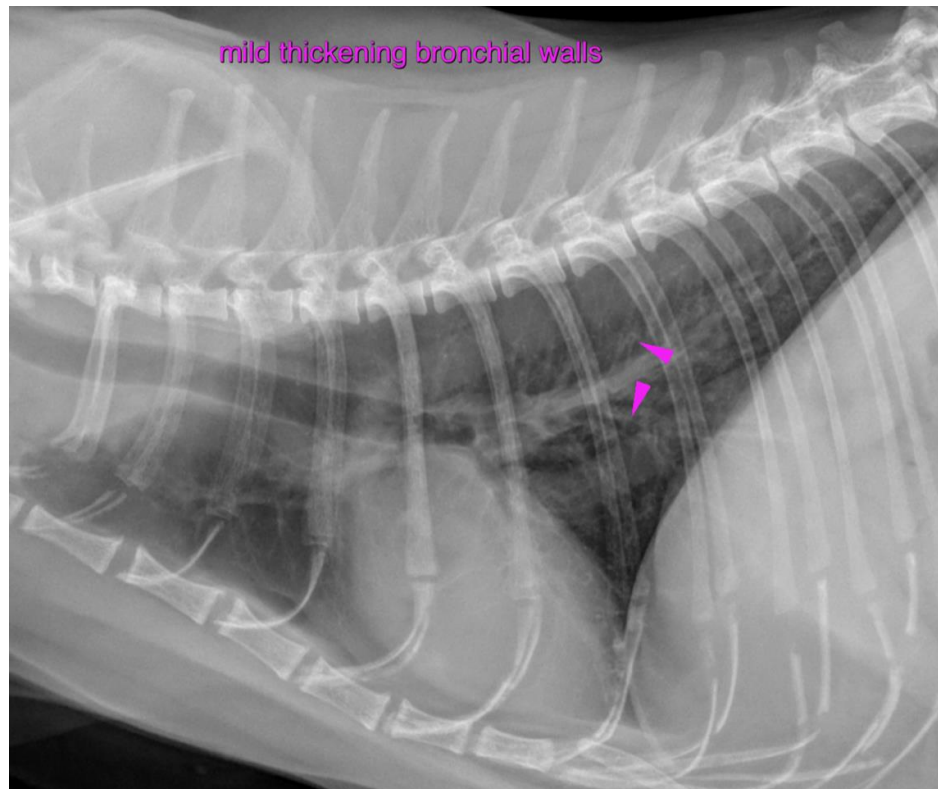
Female Spayed

AGE

12 Years, 3 Months

INTERPRETED BY

Sebastian Schaub, DVM
Dr. med. vet. DipECVDI



HOSPITAL NAME

Elizabeth Animal
Hospital

REFERRING VET

Dr. Leon Anderson

INVOICE

50696

DATE

3-3-22

The information and recommendations provided are based on the images presented by the referring veterinarian/sonographer. No evaluation can be communicated regarding pathology that was not visible in the image/video clips provided.

Thank you for this referral. If the clinical or image interpretation does not parallel your findings or if I can be of any further assistance please contact me.

Sebastian Schaub, Sebastian Schaub, DVM, Dr. med. vet. DipECVDI
sebast.schaub@gmail.com