



PATIENT PRESENTING CLINICAL SIGNS

Kai Gods Light in The Darkness Intermittent RF lameness x 1-2 weeks, improved on NSAID therapy
Abnormal PE/Chem/CBC/UA Results: Mild discomfort on flexion of elbow. Remainder of PE is unremarkable. BW not performed. R/o elbow dysplasia.

SPECIES RADIOGRAPHIC STUDY OF THE RIGHT ELBOW JOINT

Canine Radiographs of the right elbow joint in two orthogonal imaging planes are provided for review. Radiographs are provided in PNG file format.

RADIOGRAPHIC FINDINGS

BREED
Yorkshire Terrier The periarticular bones of the right elbow joint present mild osteophyte new bone formation. In the mediolateral projection, a triangular shaped mineral opaque body is seen – not appreciated in the craniocaudal view. The medial coronoid process of the coronoid process is ill-defined.

RADIOGRAPHIC DIAGNOSIS

- SEX**
MN
- Isolated mineralized body cranial aspect of the humeral condyle
 - Possible coronoid disease right elbow joint
 - Mild degenerative osteoarthritis right elbow joint

AGE INTERPRETATION OF THE FINDINGS & FURTHER RECOMMENDATIONS

1 Year The findings are suggestive for coronoid disease of the right elbow joint and can be a potential source for the right front limb lameness – although coronoid disease is a common entity in large breed dogs it can be sporadically appreciated in small breed as well.

INTERPRETED BY

Sebastian Schaub, DVM
Dr. med. vet. DipECVDI

The mineralized body at the cranial aspect of the right elbow joint can present metaplasia, synovial osteochondromatosis or displaced fragment.

HOSPITAL NAME

Check if pain can be elicited by pressure on the medial compartment of the right elbow joint supporting the diagnosis. A CT study of the elbow joints can be used as advanced imaging modality.

Ruidoso Animal Clinic

REFERRING VET

Sarah Botkin

INVOICE

57528

DATE

3-29-23



PATIENT

Kai Gods Light in The
Darkness

SPECIES

Canine

BREED

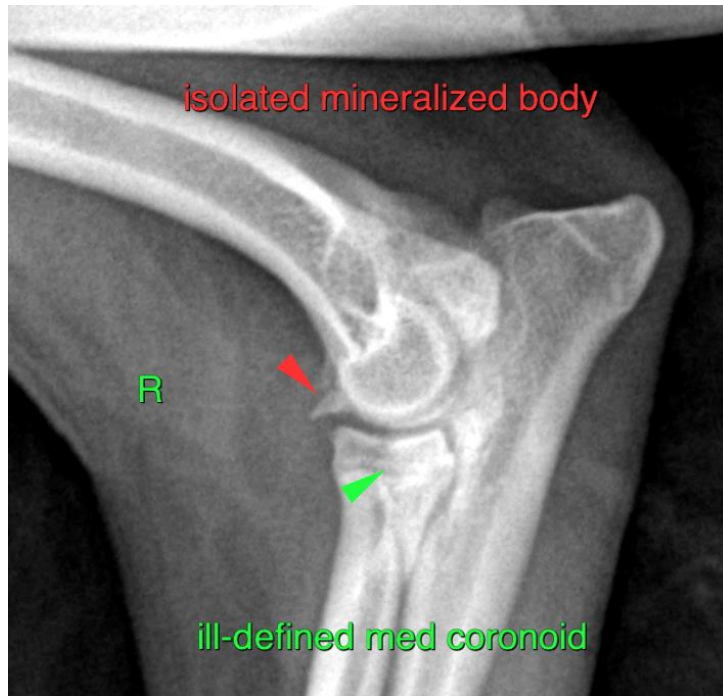
Yorkshire Terrier

SEX

MN

AGE

1 Year



INTERPRETED BY

Sebastian Schaub, DVM
Dr. med. vet. DipECVDI

The information and recommendations provided are based on the images presented by the referring veterinarian/sonographer. No evaluation can be communicated regarding pathology that was not visible in the image/video clips provided.

HOSPITAL NAME

Ruidoso Animal Clinic

Thank you for this referral. If the clinical or image interpretation does not parallel your findings or if I can be of any further assistance please contact me.

Sebastian Schaub, Sebastian Schaub, DVM, Dr. med. vet. DipECVDI
sebast.schaub@gmail.com

REFERRING VET

Sarah Botkin

INVOICE

57528

DATE

3-29-23